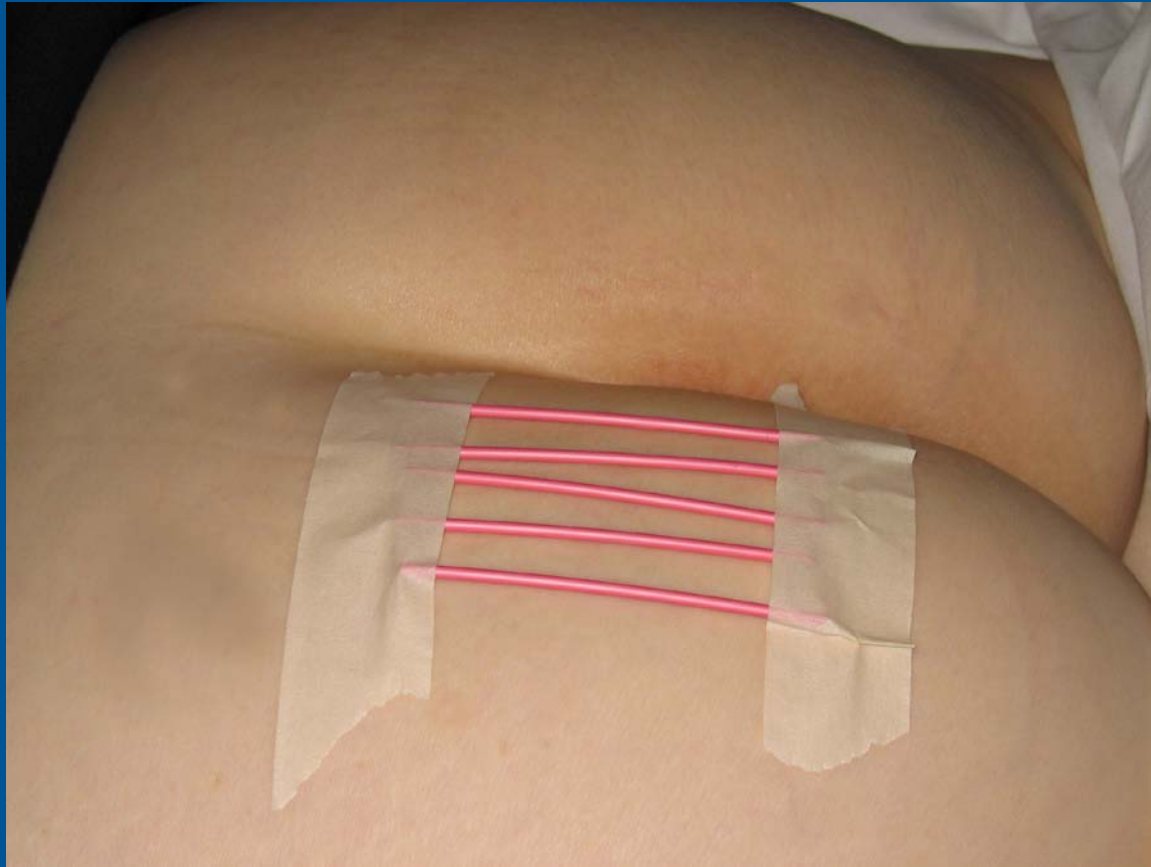


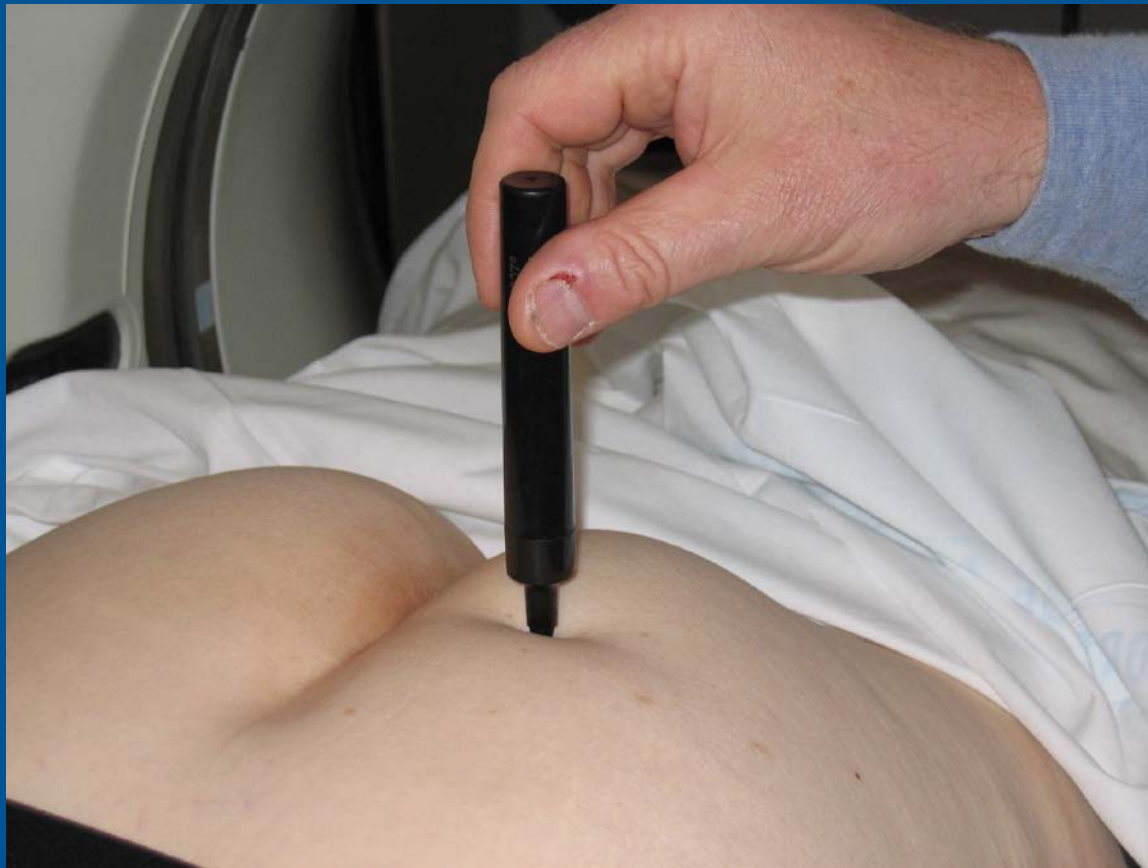How to do Pudendal Nerve Blocks

P-L Westesson, M.D., Ph.D., D.D.S.
FM Howard, Jr., M.D., M.S.
and A Hiwatashi, M.D.



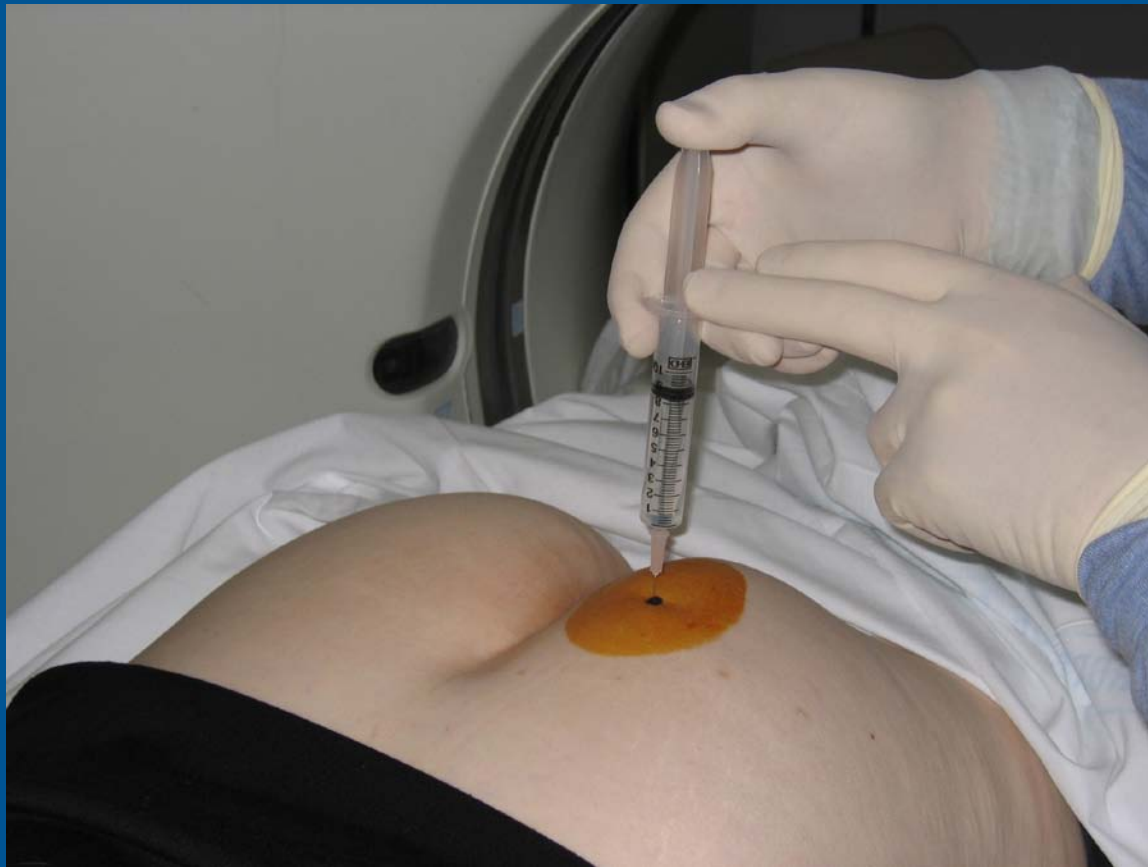- 1. Catheter tubing taped to the patient's skin to provide orientation of needle placement with CT guidance.**

Presentation material is for educational purposes only. All rights reserved. ©2004 URM C Radiology



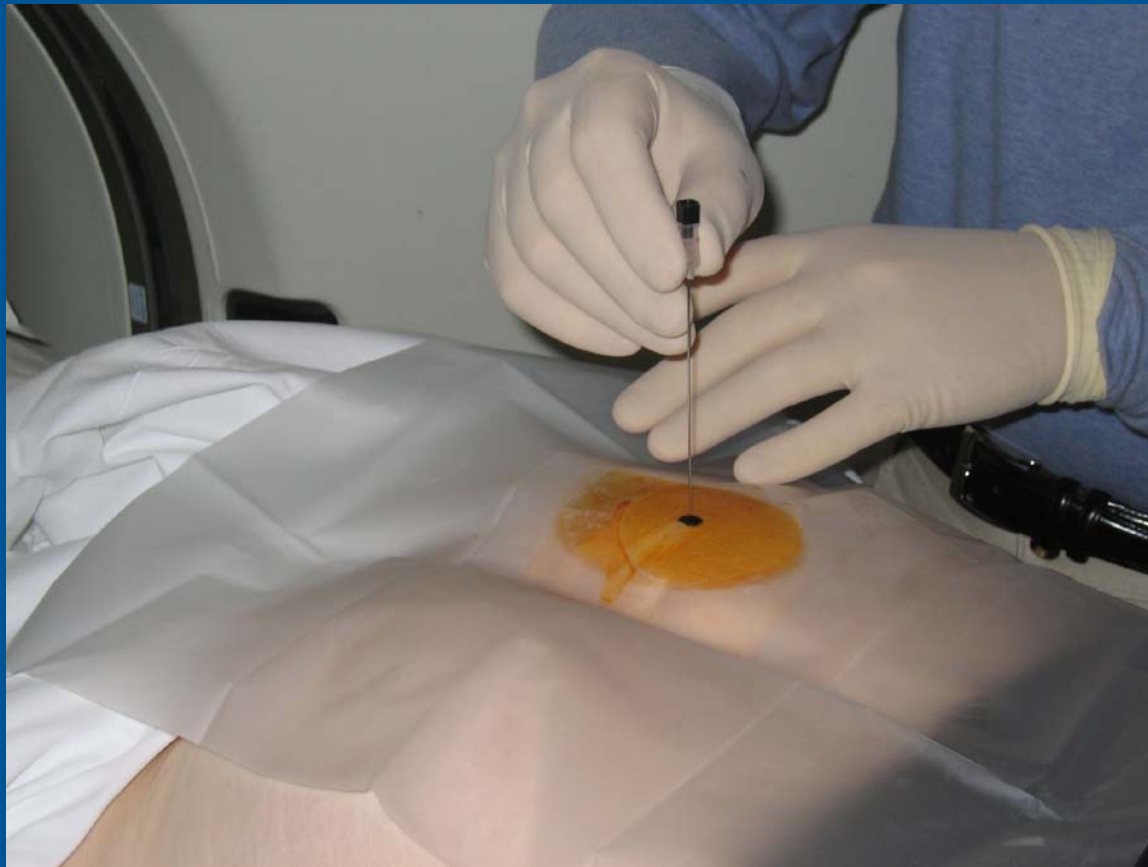2. Marking of the skin with a permanent marker.

Presentation material is for educational purposes only. All rights reserved. ©2004 URM C Radiology



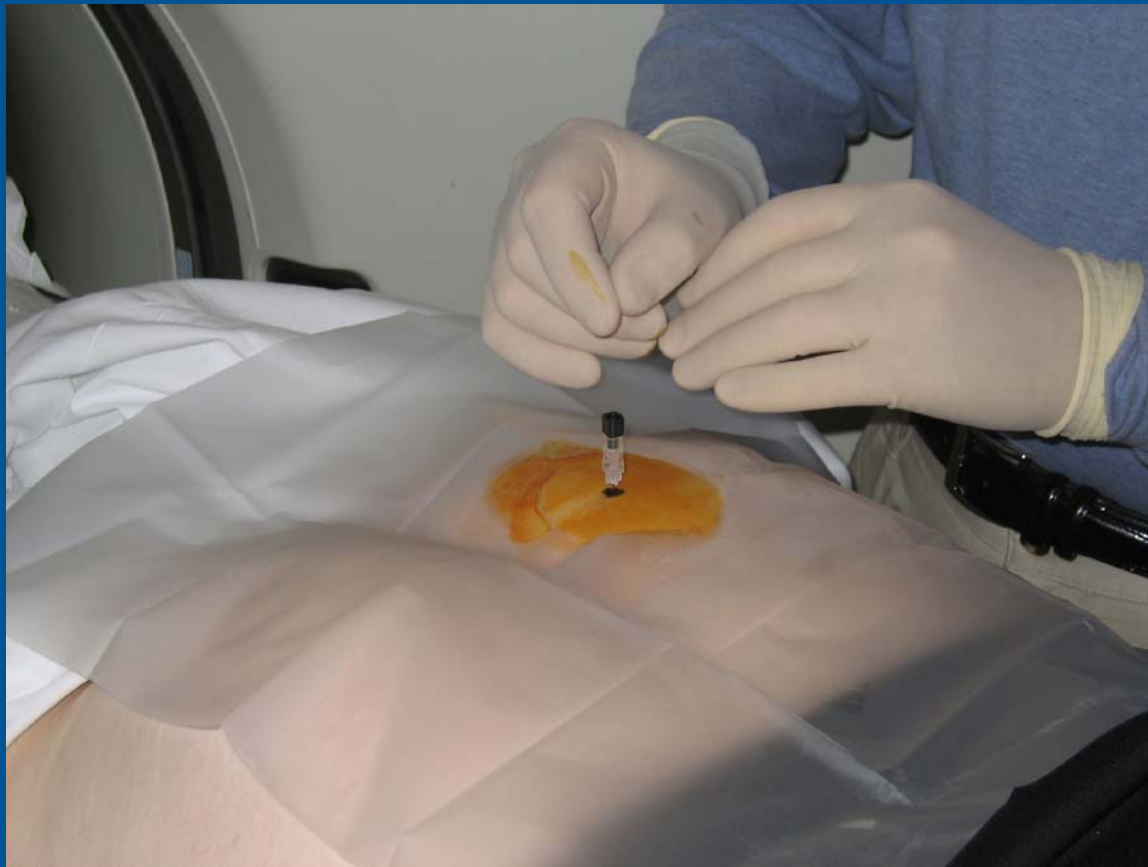3. Local anesthetics (1% Lidocaine).

Presentation material is for educational purposes only. All rights reserved. ©2004 URM Radiology



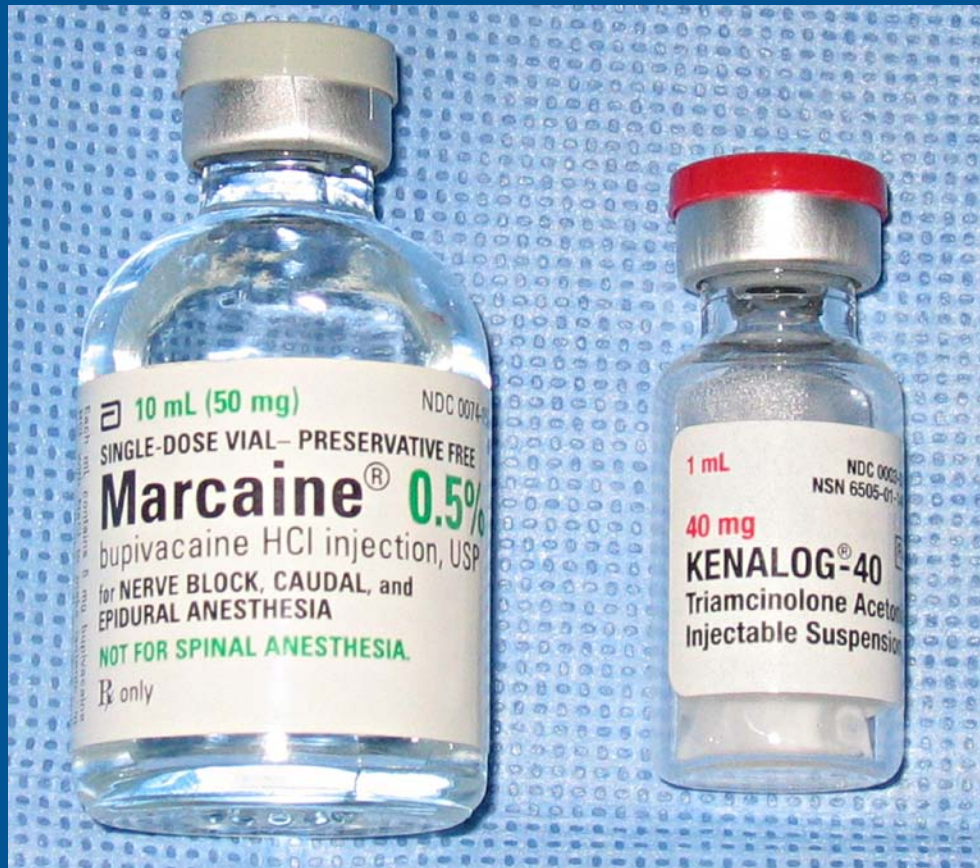4. 22-gauge 3.5 inch spinal needle.

Presentation material is for educational purposes only. All rights reserved. ©2004 UPMC Radiology



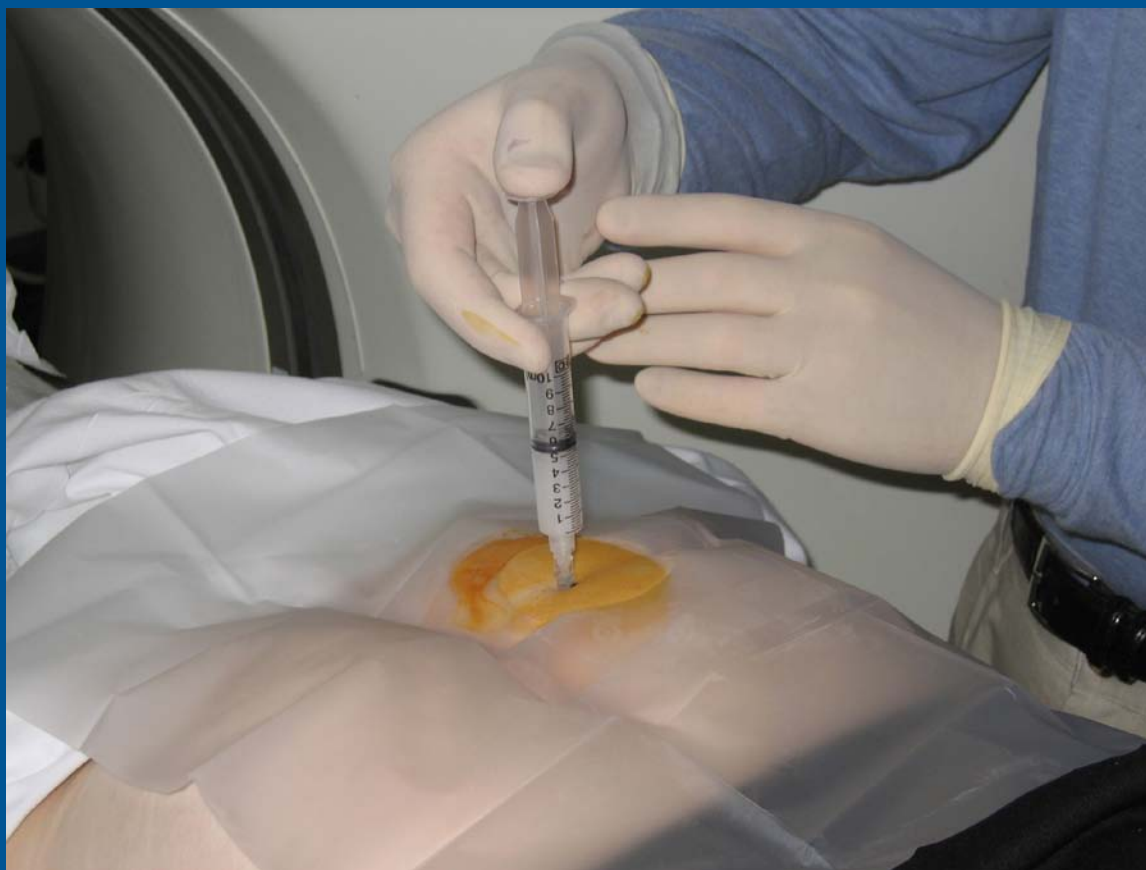5. Needle in place for CT check.

Presentation material is for educational purposes only. All rights reserved. ©2004 URM C Radiology



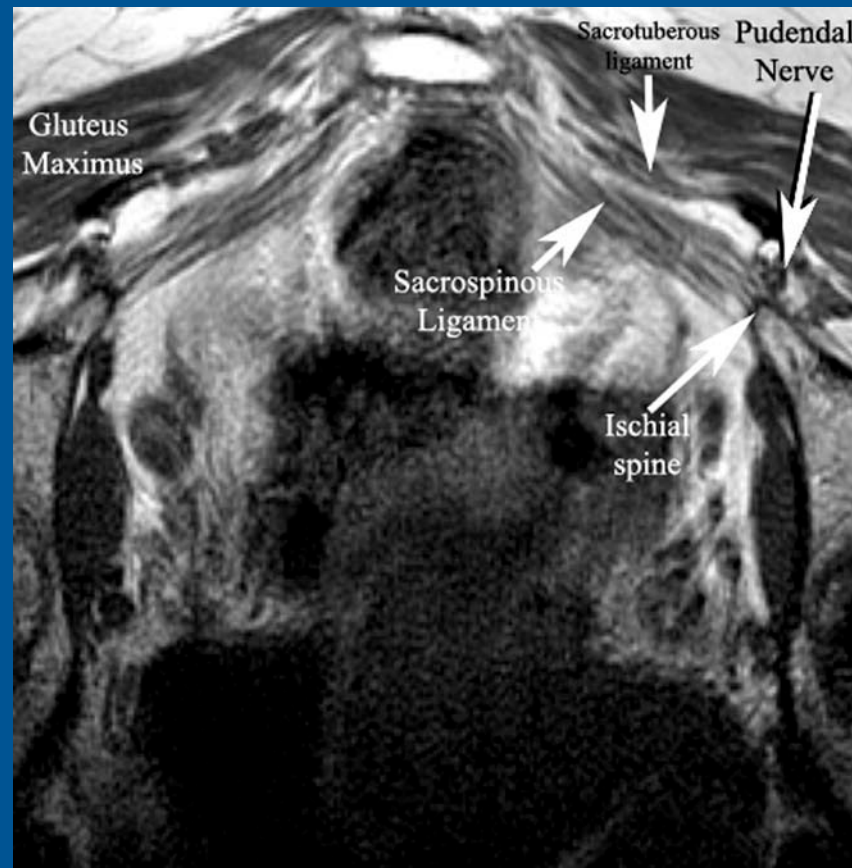6. Medications used: Marcaine 0.5% and Kenalog 40 mg/mL

Presentation material is for educational purposes only. All rights reserved. ©2004 URMC Radiology

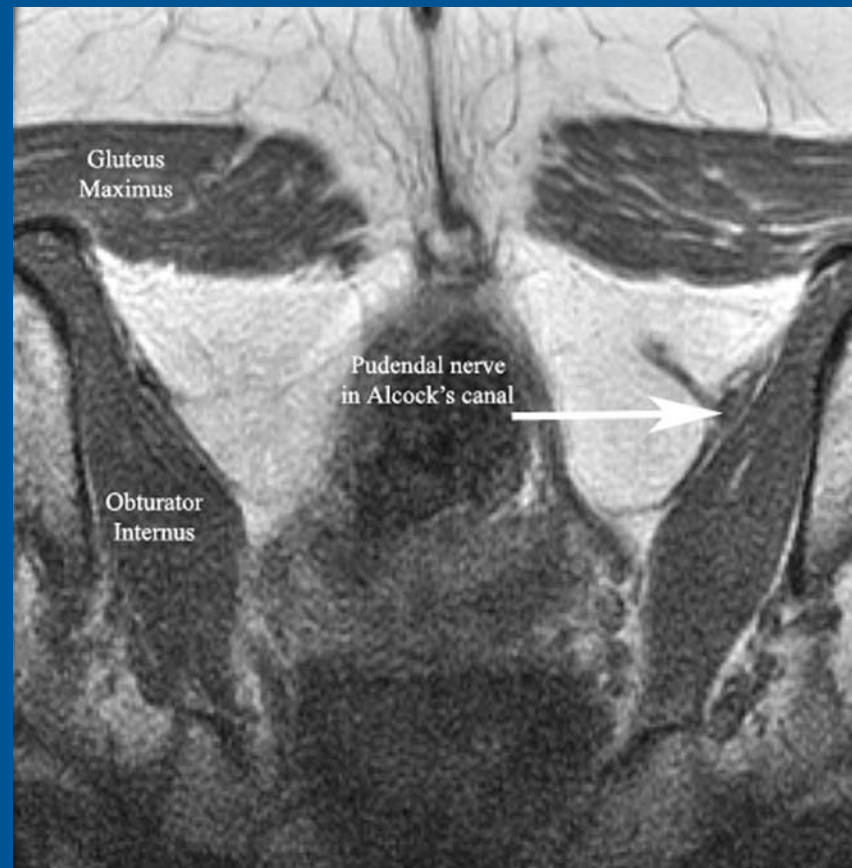


7. Medication injected.

Presentation material is for educational purposes only. All rights reserved. ©2004 URM C Radiology

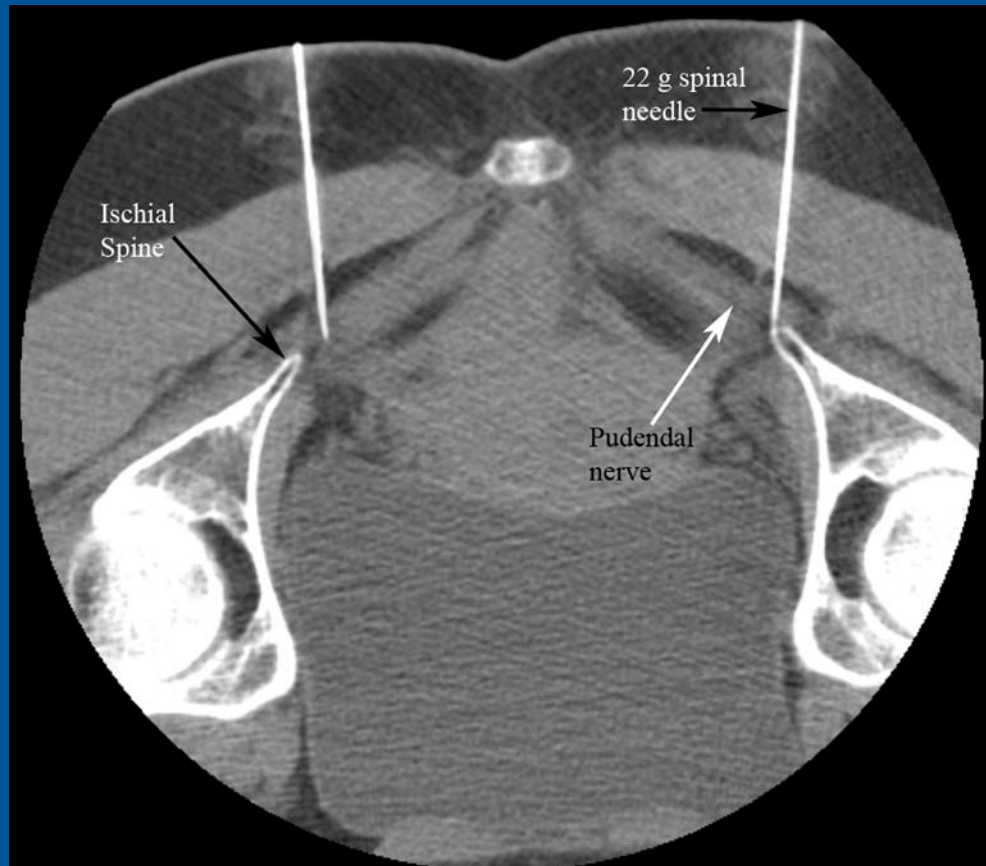


Pudendal nerve at ischial spine.



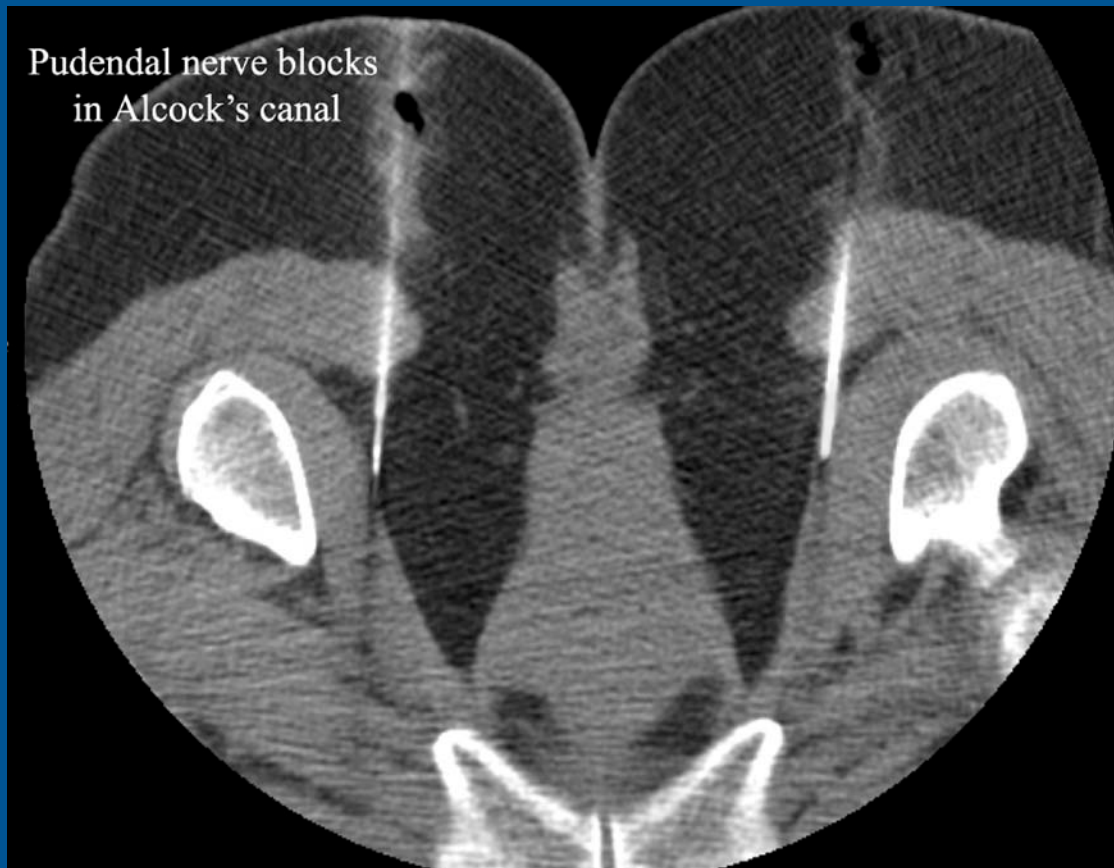Pudendal nerve in the Alcock's canal

Presentation material is for educational purposes only. All rights reserved. ©2004 URM Radiology



Pudendal nerve block at ischial spine

Presentation material is for educational purposes only. All rights reserved. ©2004 URM C Radiology



Pudendal nerve block in the Alcock's canal

Presentation material is for educational purposes only. All rights reserved. ©2004 URM C Radiology