

MAGNETIC RESONANCE MYELOGRAPHY



HUMERA AHSAN, M.D. F.C.P.S.

DEPARTMENT OF RADIOLOGY & IMAGING
AGA KHAN UNIVERSITY HOSPITAL



- Magnetic Resonance Myelography is a relatively new imaging sequence which produces myelogram like images of the thecal sac by MR imaging.

Advantages

- It is totally non invasive and patient friendly.
- Has no side effects from intra-thecal contrast.
- No exposure to ionizing radiation.
- Short imaging time.
- Both the superior and inferior extent of spinal block are shown.

Technique

Single shot TSE, TR 8000 ms, TE 1000 ms, TSE factor 256, acquisition time 3:36.

MR myelographic images are automatically reconstructed as maximum intensity projections and presented as 9 consecutive images at 22.5° intervals, extending from a right lateral to a left lateral projection.

Why MR Myelogram?

- The main indication of MR myelography is in the evaluation of low back pain
- The methods which are currently available for the imaging of spine include CT, CT myelography, conventional myelography and MRI.
- It has been shown that the accuracy of the diagnosis in discogenic disease is higher when a combination of two imaging modality is used.

Cont.

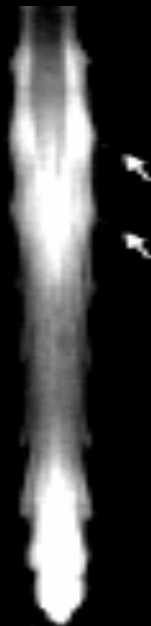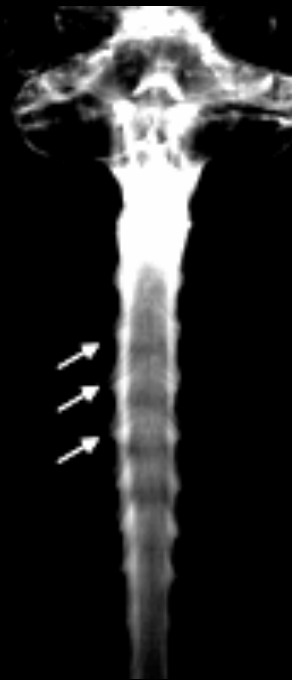- *There was 92.5% agreement between the surgery and the findings when CT and MR were used jointly used.*

Modiac MT, Masaryk T et al 1986 AJNR 7 : 709 - 717

Presurgical evaluation

MRI has become the single most useful imaging test for evaluation of patients with back pain and is accepted as the gold standard, however myelography is needed in cases where the exact topographic correlation of the spinal nerve roots to the bony or discogenic structures has to be verified preoperatively.

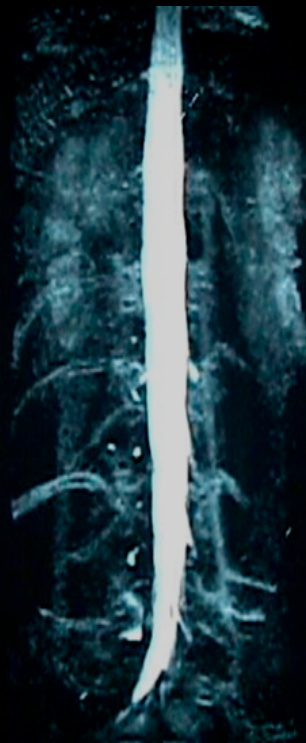
Myelography is also needed to assess the degree of pressure on the thecal sac and the level of maximum pressure.



L10
=160



L10



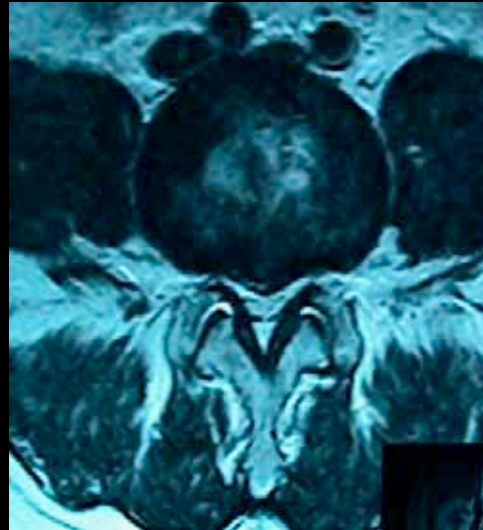
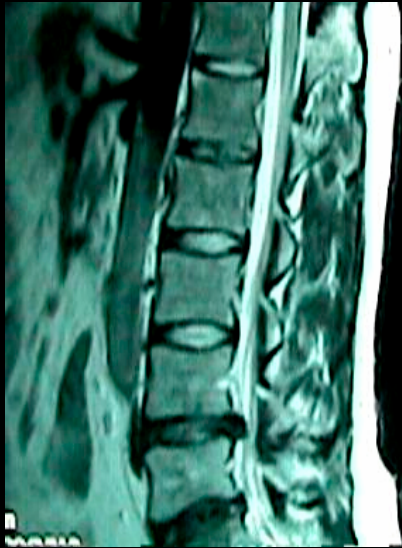G3-10:
L10

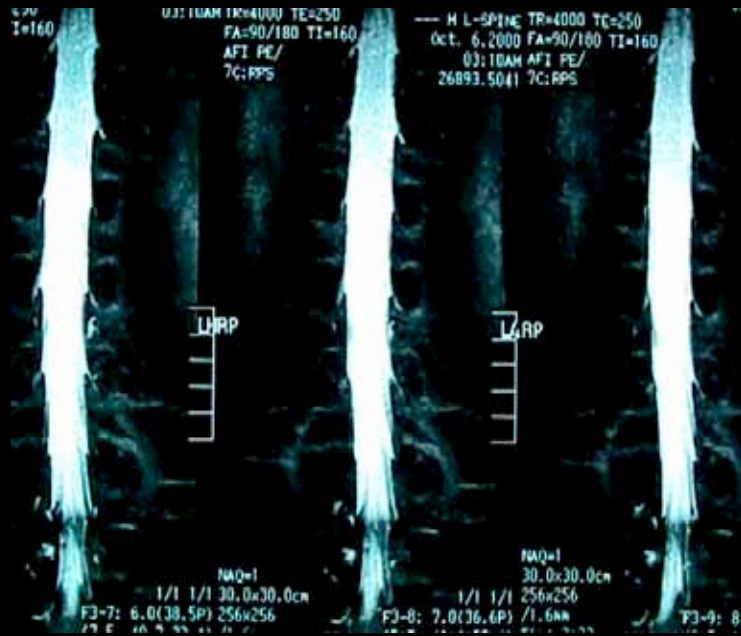
Disk Herniations

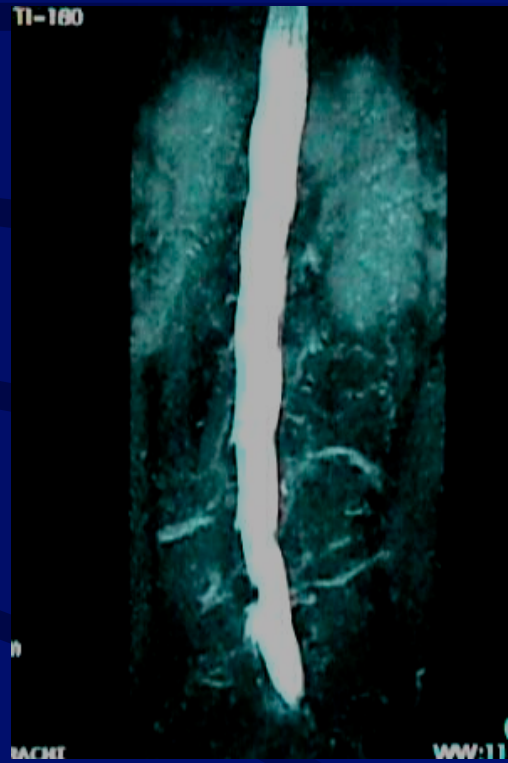
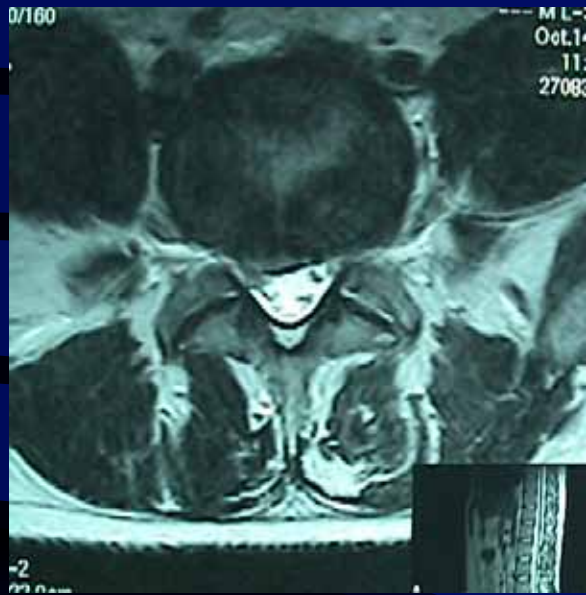- MR myelography shows focal deformity of thecal sac margin due to disk herniation.

Oblique MR myelography reveals extrinsic deformity of lateral recess of the thecal sac margin due to posterolateral disk herniation.

- Far lateral disk herniation, which does not affect the thecal sac, cannot be detected on MR myelography.







- *The sensitivity for detecting and localizing CSF root sheath / nerve root in patients with nerve root compression is higher using 3 D MRM (90.6%) compared to conventional myelography (81.4%)*

K.E.W Eberhardt et. al 3 D MRM of lumbar spine. Eur Radiol 7, 737 - 742 (1997)

Nerve root compression

Although MRI provides superior diagnostic information regarding the spinal cord and spinal canal, results are sub optimal in delineation of foraminal pathology in cervical spine

MR myelography helps in the detection of foraminal disease in two ways.

First, the heavily T_2 weighted nature of the technique results in high contrast between the CSF and all other soft tissue structures, including disk material, this allows the demonstration of foraminal disk protrusions that would otherwise are less easily detected on conventional axial T_2 weighted images.

Second, any possible abnormality seen on MR myelography prompts a re-evaluation of the relevant axial and sagittal sequences and produces an increased rate of detection of foraminal compression as a result of this review process.

Although MRM did not significantly improve the diagnostic accuracy of MRI, it allowed a better overall view of the dural sac and root sleeves, therefore making it easier to diagnose spinal stenosis and disc herniation in a minority of cases

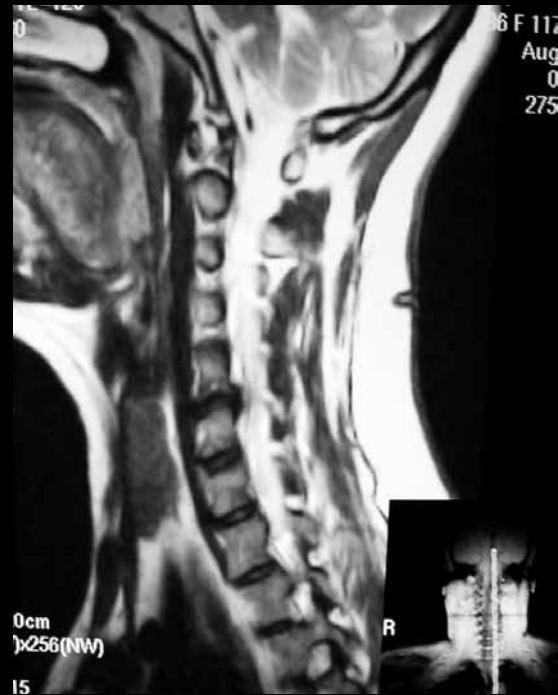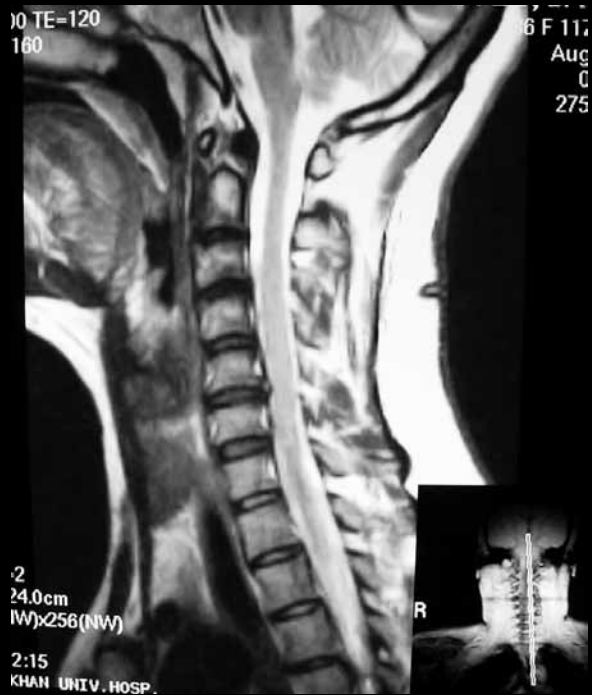*Pui M.H.; Husen Y.A. Australasian Radiology
August 2000, vol. 44, no. 3, pp. 281-284(4)*

Nerve root Compression

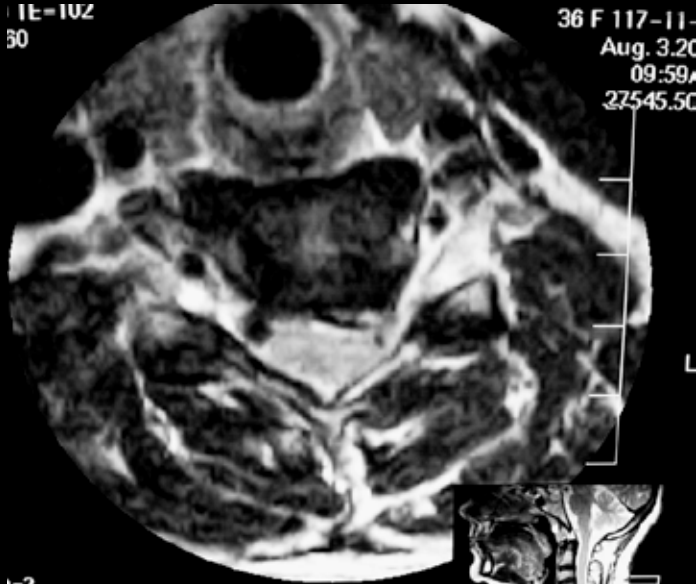
MR myelography may be a useful adjunct to conventional axial and sagittal imaging in the investigation of cervical spondylotic radiculopathy.

The use of MR myelography increased the number of compressive foraminal stenoses positively identified and it has the potential to reduce the need for subsequent CT myelographic examination

British Journal of Radiology (2003) 76, 525-531



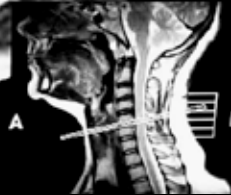TE=102
30



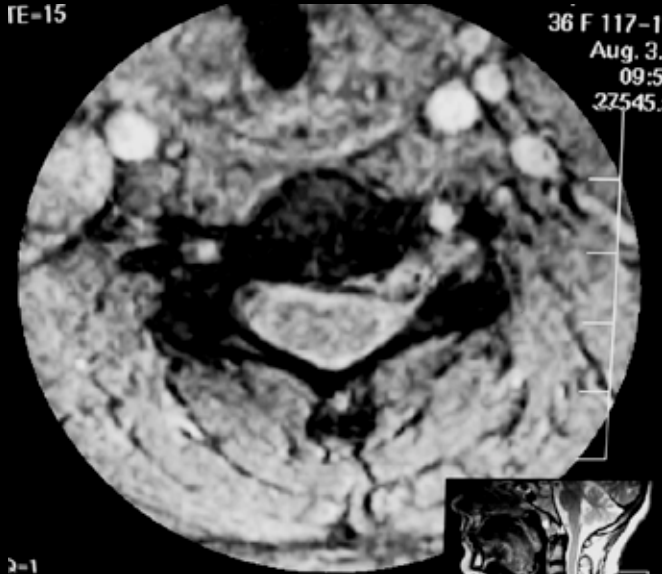
36 F 117-11-
Aug. 3.20
09:59,
27545.5C

L

l=2
x15.0cm
256
m
e 2:14

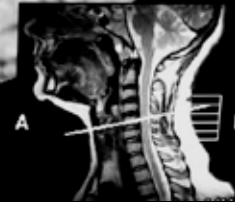

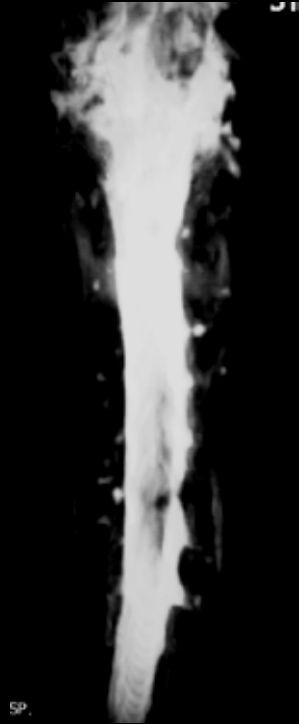
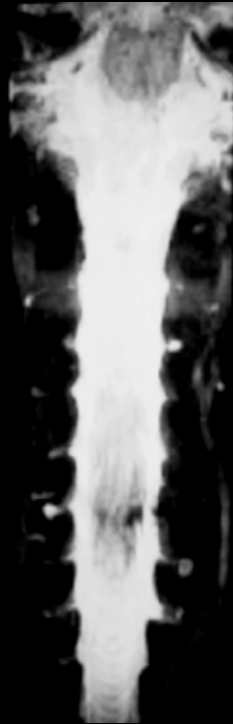TE=15



36 F 117-1
Aug. 3.
09:5
27545.

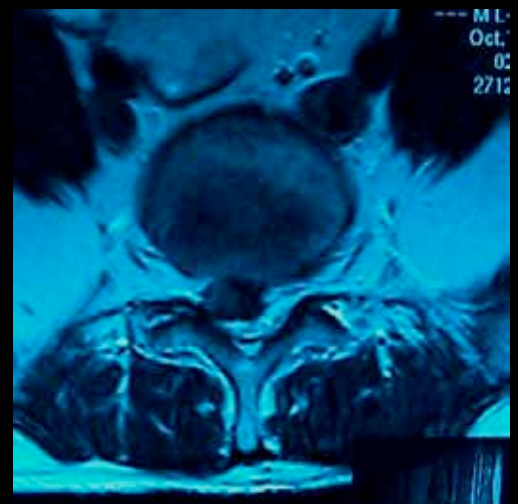
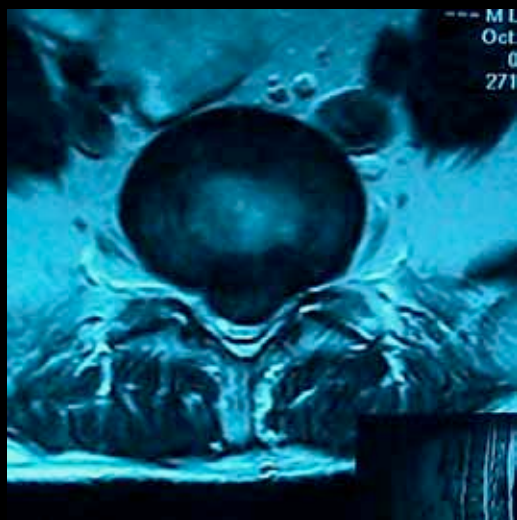
2=1
x15.0cm
x256 (NW)
im
te 4:05
K. KHAN UNIV. HOSP

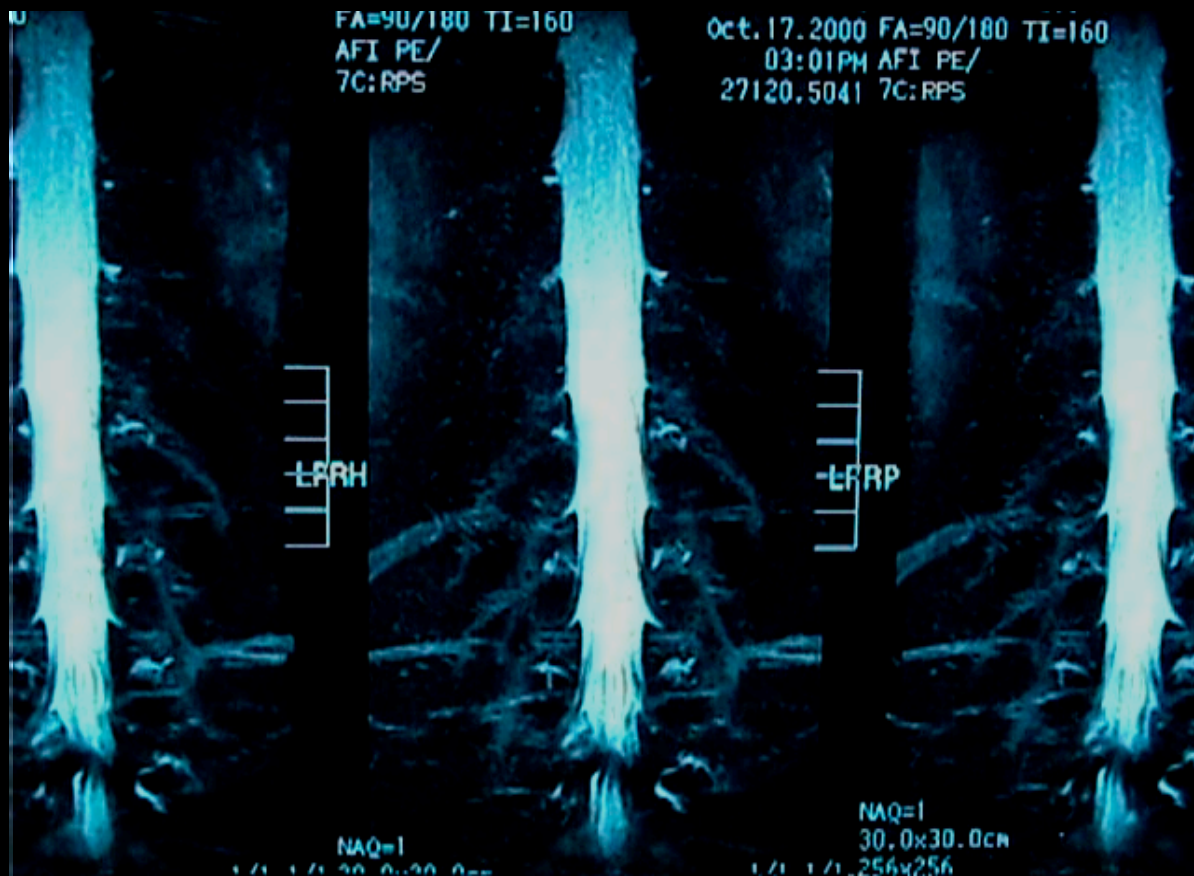




Disc Migration

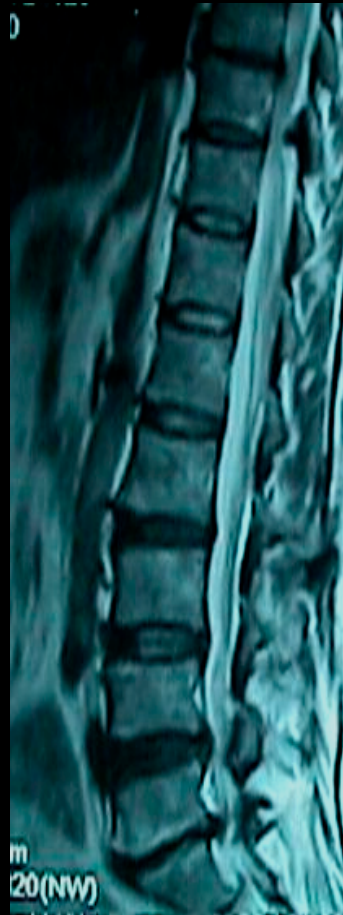- The herniated disc may affect the nerve root above it if there is lateral and upward migration of a free fragment into the neural foramen.
- This will be seen as filling defect at the origin of nerve root sleeve or obliteration of nerve root sleeve.

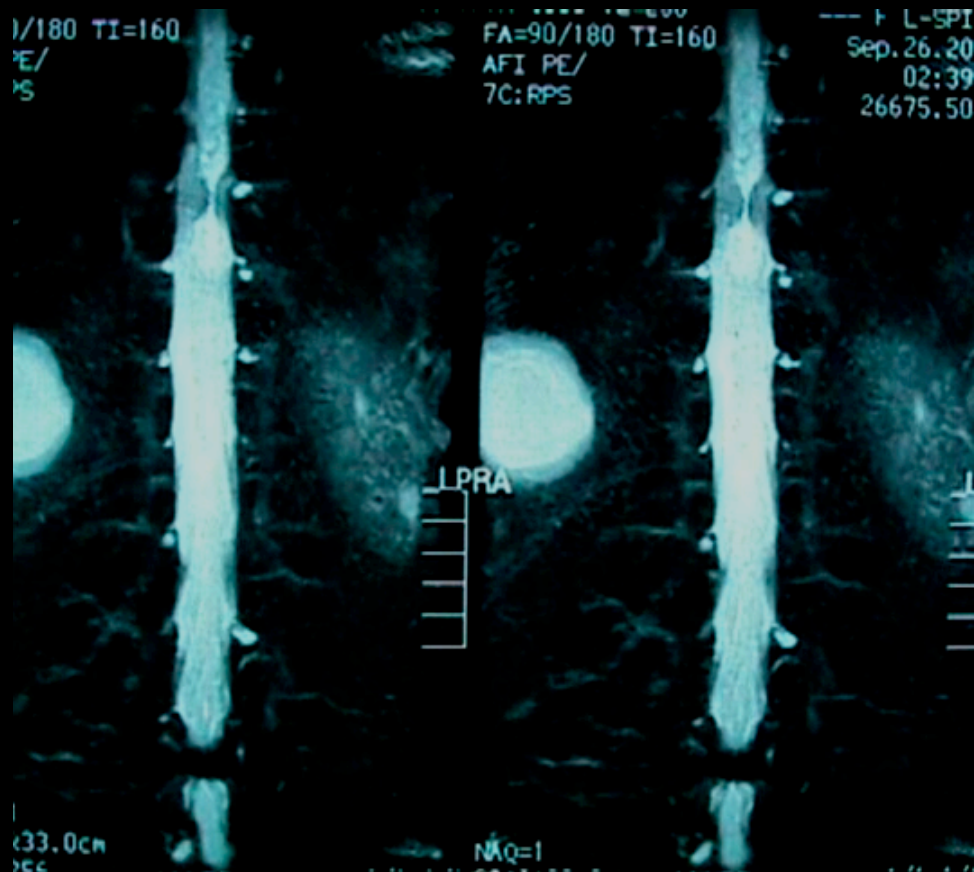


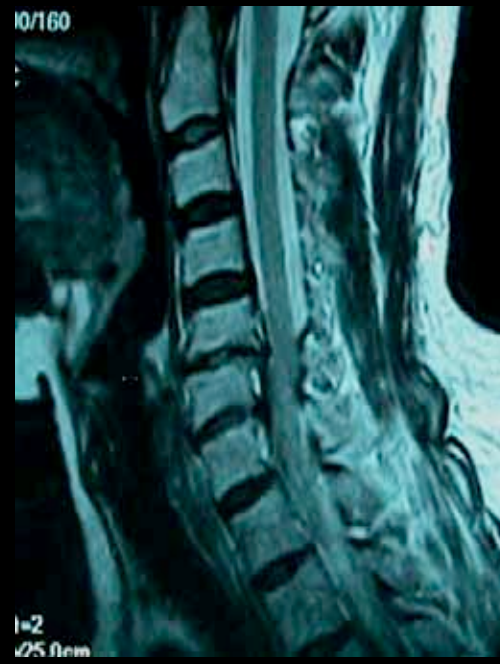
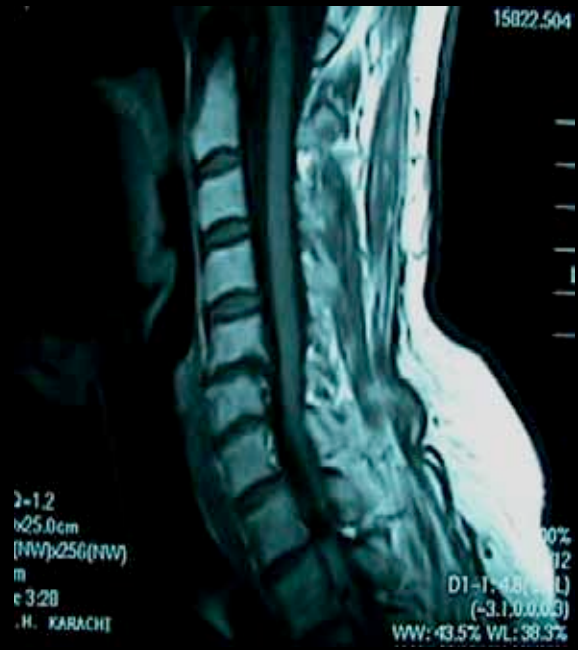
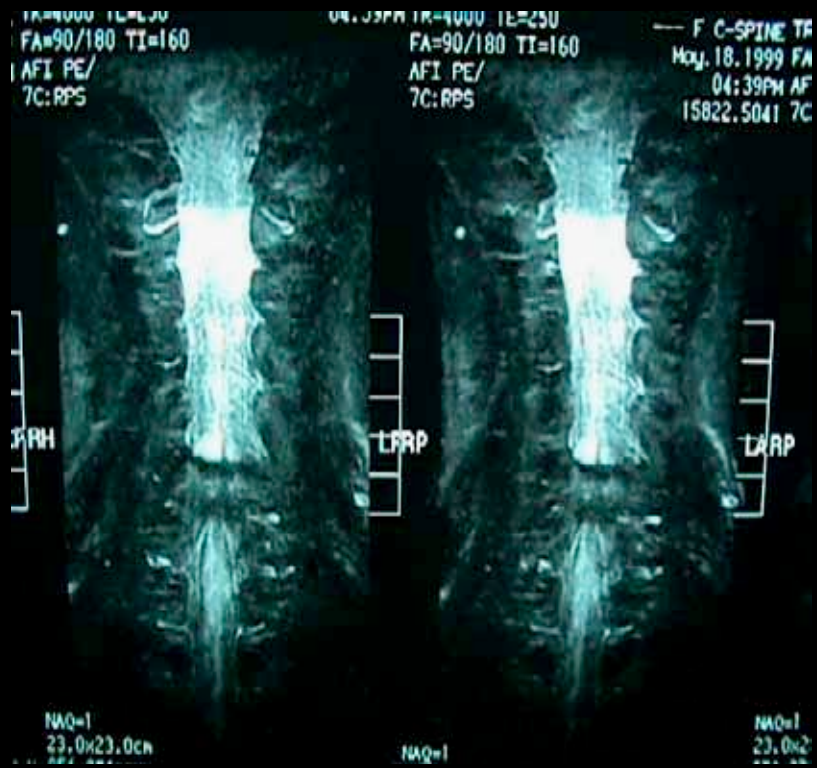
Facet arthrosis syndrome.

- Facet joint hypertrophy can cause pressure on the thecal sac which can be appreciated by MR myelogram.
- Pressure caused by hypertrophy of ligamentum flavum can also be seen on MR myelograms.





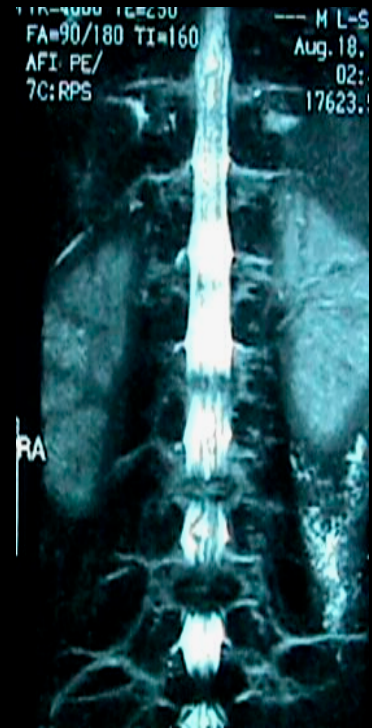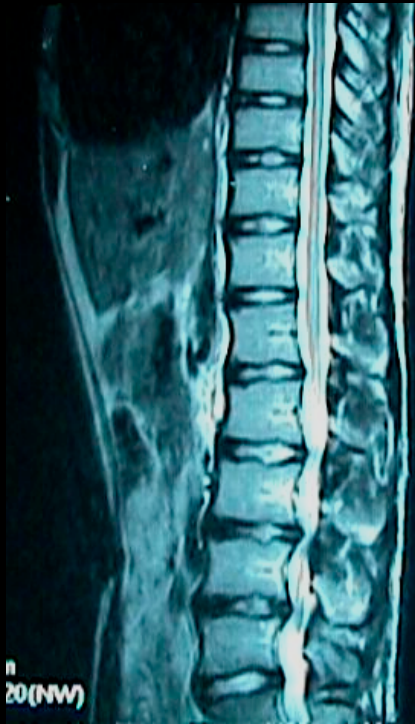




Spinal Stenosis

The thecal sac is effaced anteriorly by the bulging discs and posterolaterally by the ligamentum flavum and hypertrophied facets resulting in an hourglass configuration with progressive stenosis. The amount of CSF progressively diminishes and the nerve roots become crowded together.

As a result of epidural compression prominent enhancement of retrovertebral venous plexus is common and is very well seen on MR myelograms.

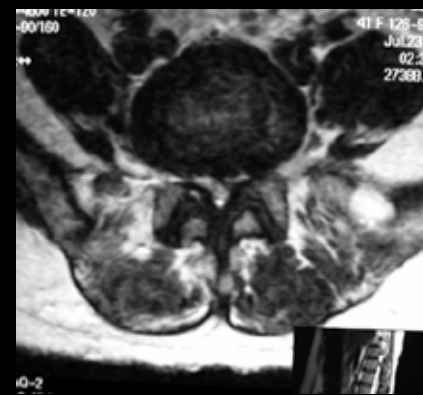
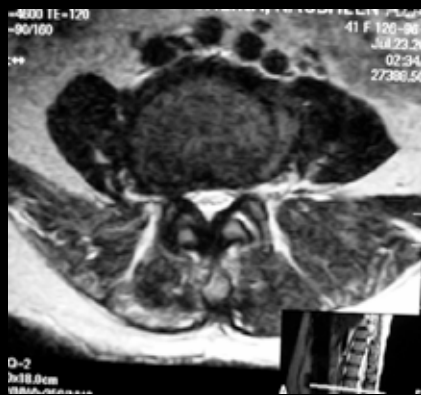
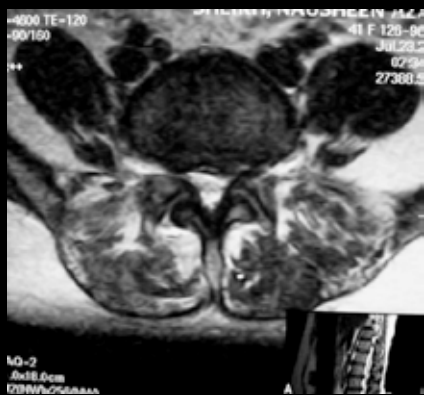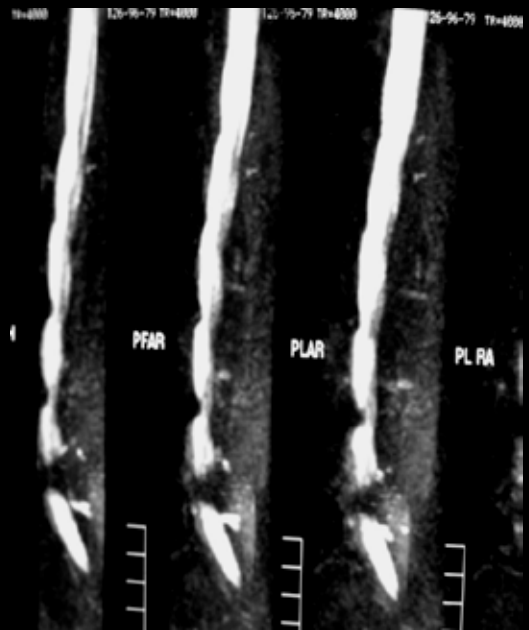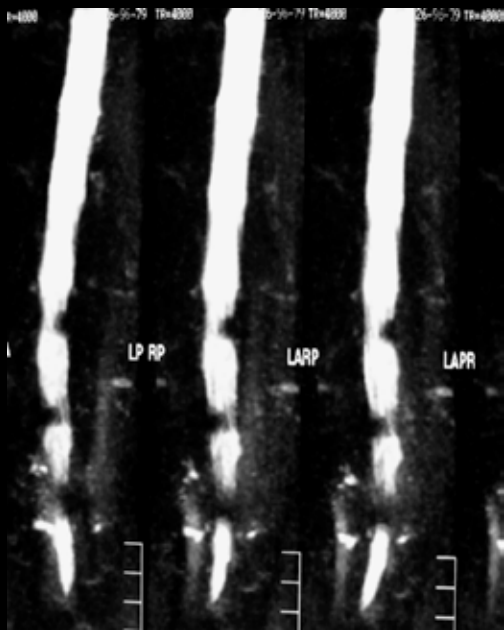
The sensitivity of patients with canal stenosis is higher using 3D MRM (92.5%) than conventional X-ray myelography (82.5%)

K. E. W Eberhardt et. al Eur. Radiol 7, 737. 1997.

Assessment of Severity of Canal Stenosis

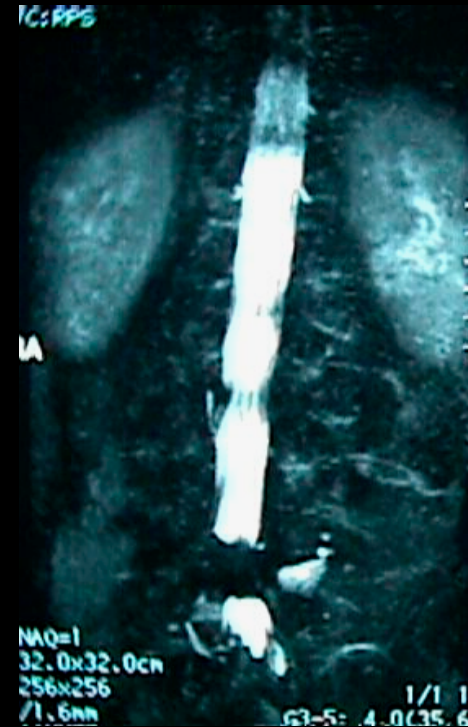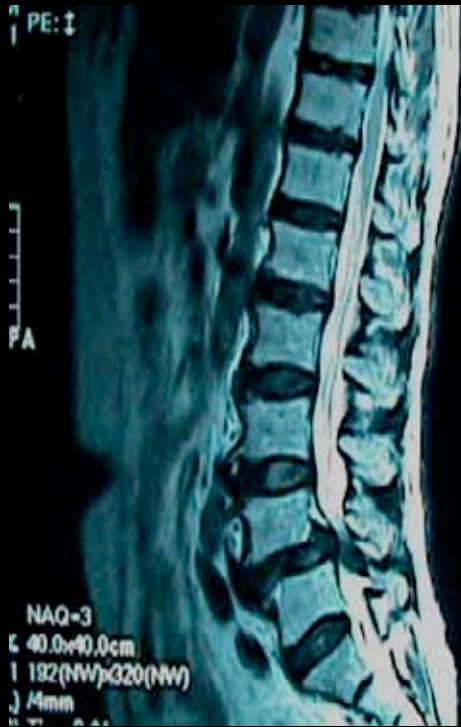- In cases of spinal stenosis at multiple levels MRM can assess the severity of stenosis at a certain level.





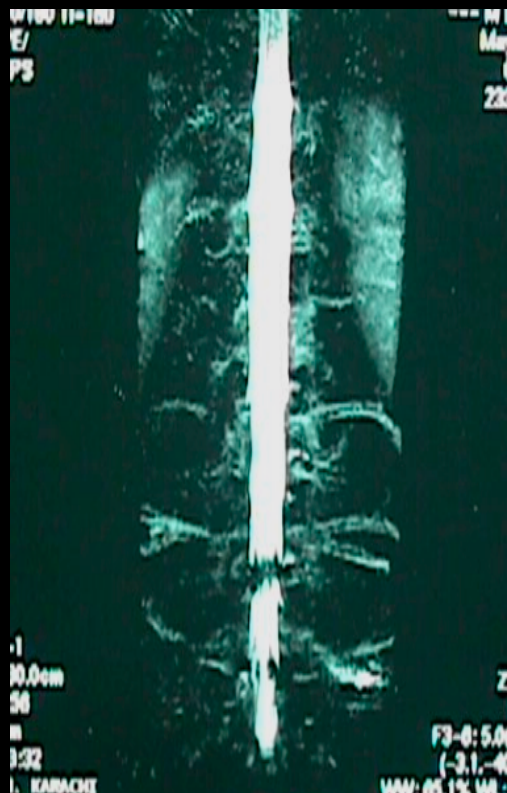
Spondylolisthesis

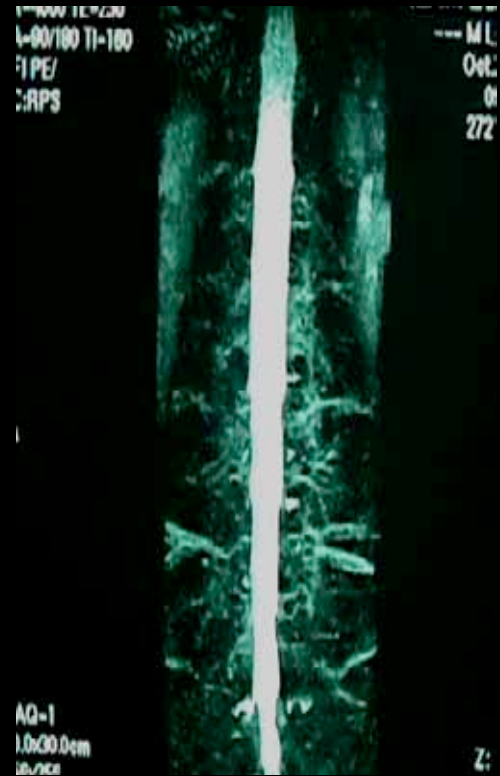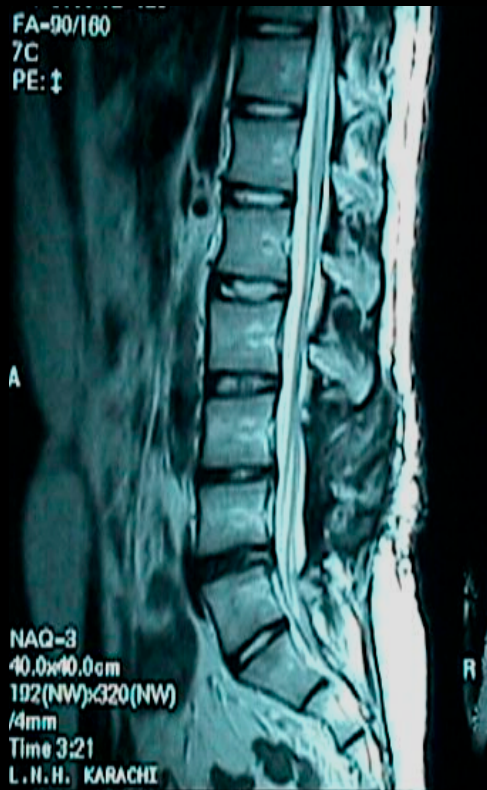- In isthmic type (pars defect) the spinal canal elongates in its AP dimension.
- In degenerative spondylolisthesis (close arch type) the spinal canal is narrowed and pressure on the thecal sac due to hypertrophied facet can be appreciated on MR myelogram.



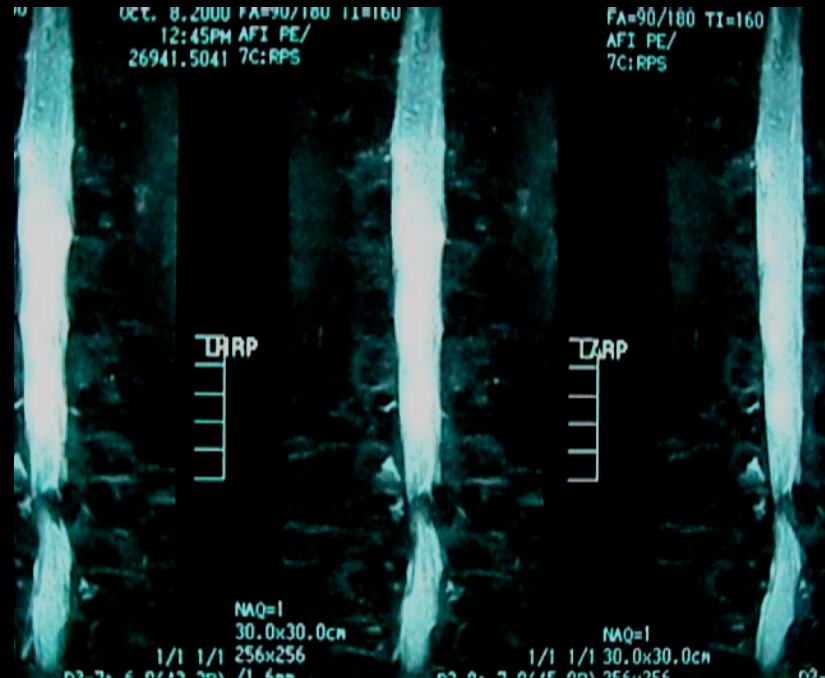
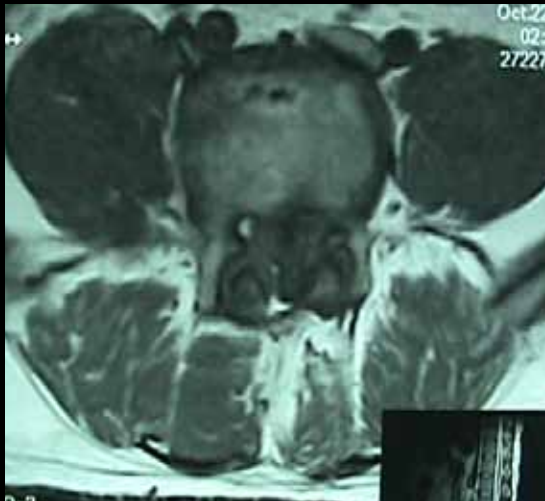Post operative spine

- The pressure caused on the thecal sac by epidural scar can be appreciated on MR myelogram, however contrast enhancement is needed to differentiate recurrent disc from the scar tissue.



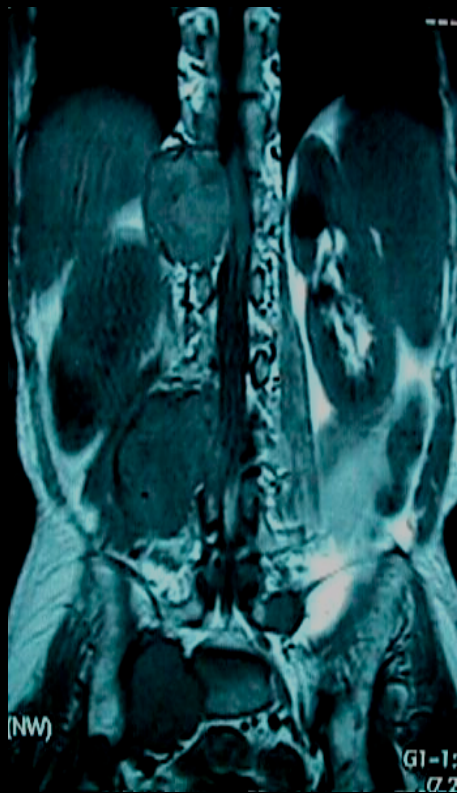


Scar tissue

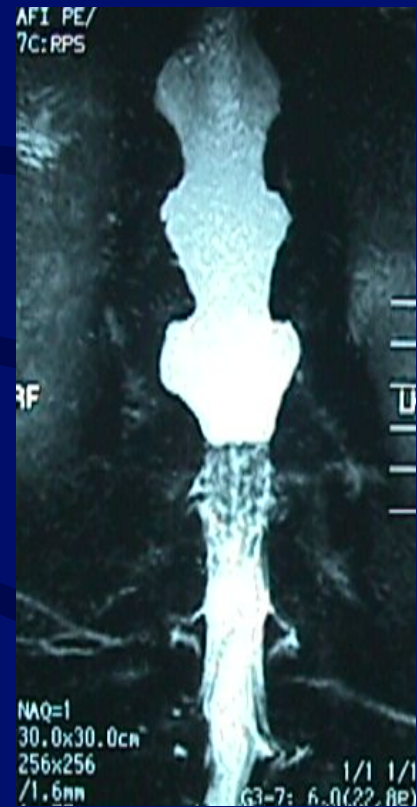
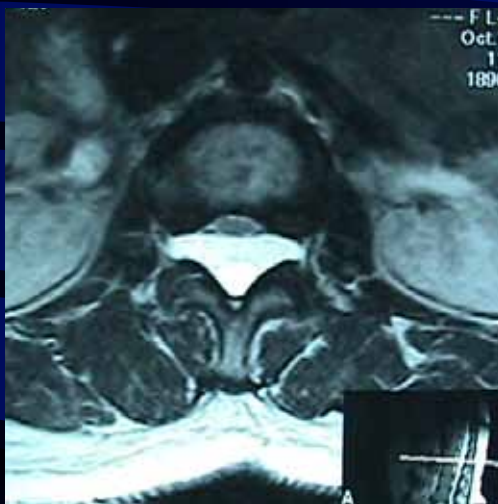
Tumors of the Spine (Extra spinal and Extradural)

- The pressure caused by the presence of tumors on the thecal sac and the extension of tumors in the spinal canal can be accurately depicted by MR myelography.
- In case of metastatic disease at multiple levels MR myelography may help the surgeon to decide the level of maximum compromise of the spinal canal.

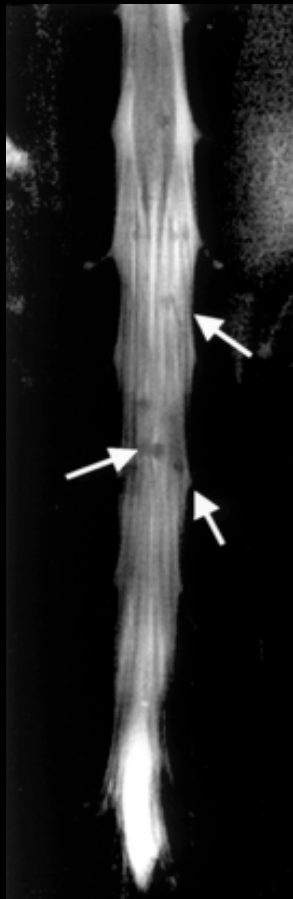


Arachnoid Cyst



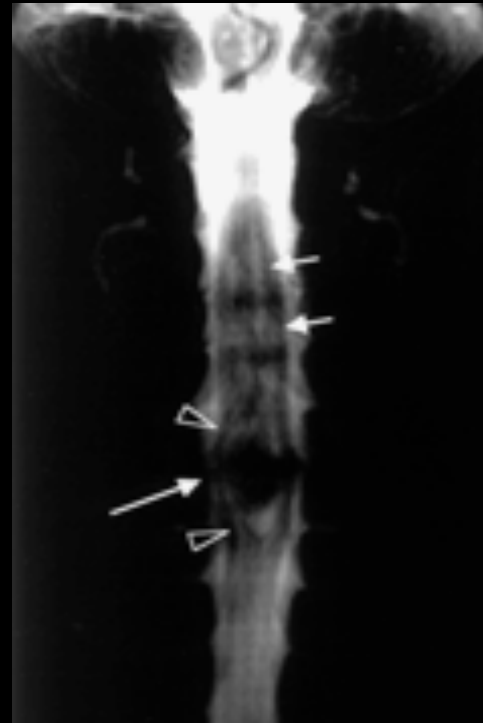
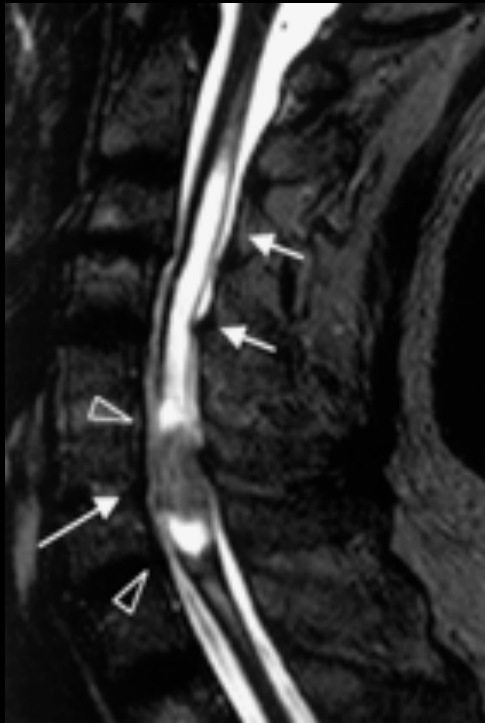Intradural Extra Medullary tumors (Neurofibroma and Meningioma)

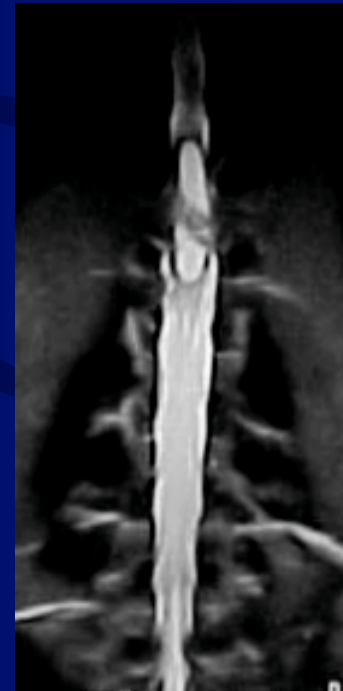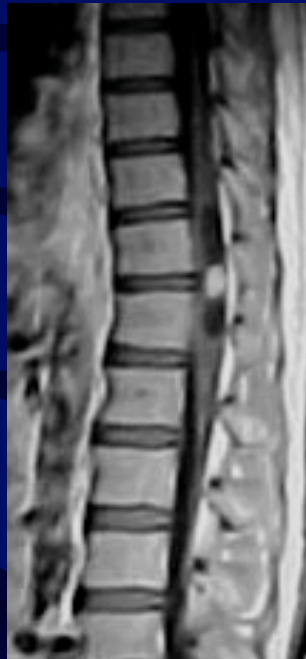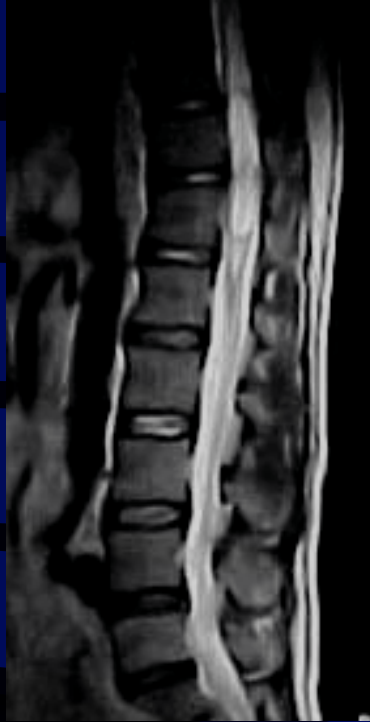
- The typical appearances of an intradural extramedullary mass is seen on myelogram. Widening of the subarachnoid space above and below and displacement of the cord is seen.
- Sometimes a small intramedullary intradural mass may only be picked up on MR myelogram as a filling defect.



Intra-medullary Tumors

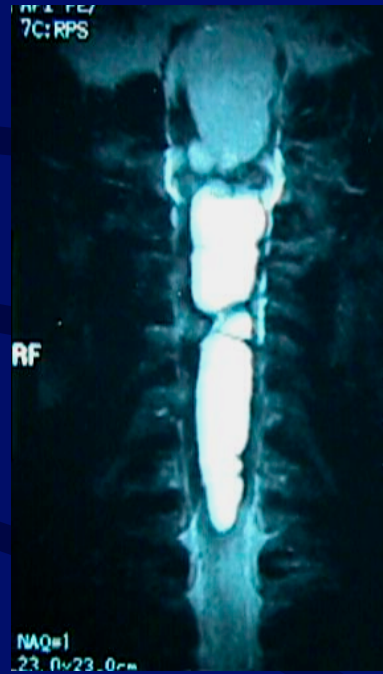
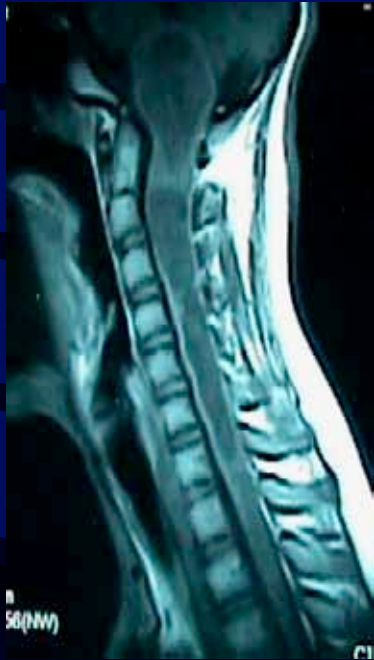- Cord expansion with narrowing of the surrounding subarachnoid space is appreciated in cases of intra-medullary tumors. The length of expansion can be identified.
- Cystic degeneration within the tumors can be seen both on MR myelogram images.





Intra-medullary Cysts

- The focal intramedullary cysts associated with ependymoma or astrocytoma, septated syrinx or simple syrinx can be identified.
- Postoperative assessment of syrinx can also be done.

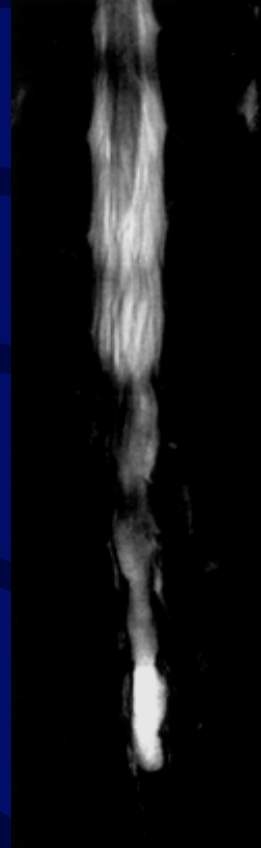
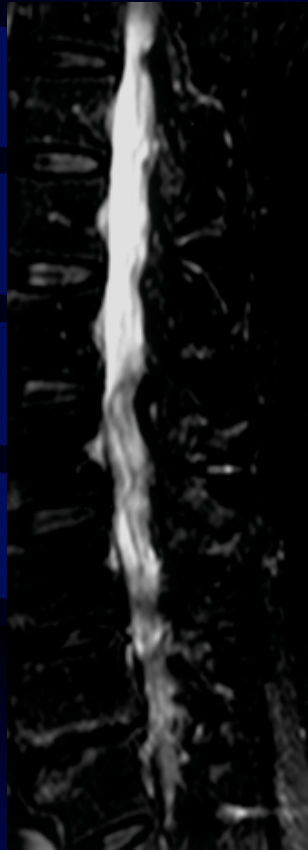


Arachnoid Adhesions

- Fibrous septas within the subarachnoid space, displacement, compression and retraction of neural elements can be clearly seen on MR myelogram suggesting the diagnosis.

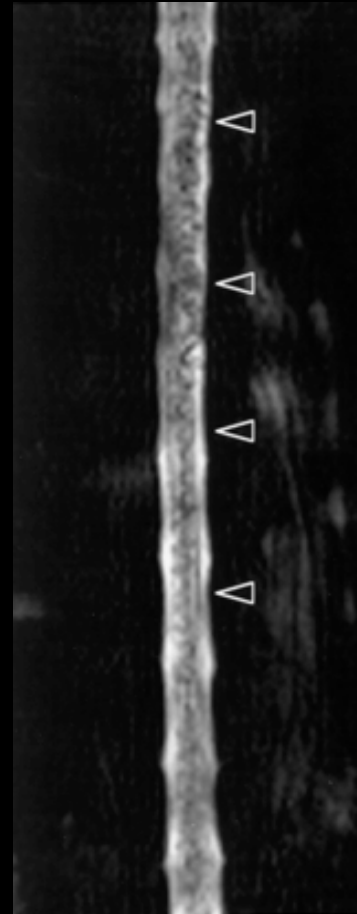
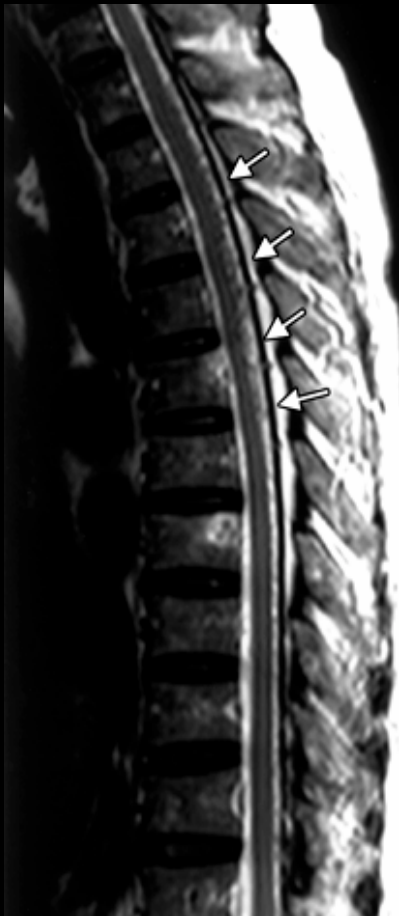MRM clearly depicts the arachnoid adhesions which are not adequately seen on conventional MR imaging and could avert the need for intra-thecal contrast myelography

Taher EL Gammal et.al AJR : 164 January 1995



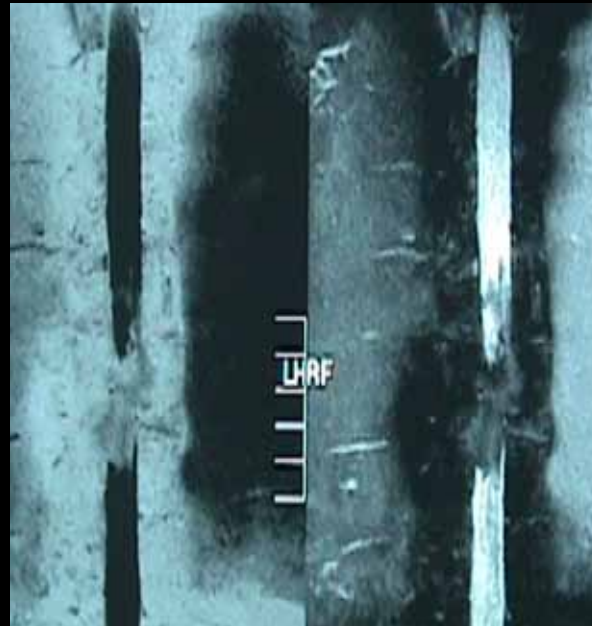
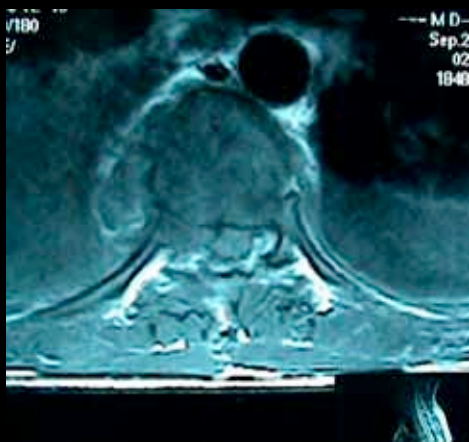
Dural Vascular Malformations

- Serpentine filling defects and large draining veins within the subarachnoid space can be easily identified.



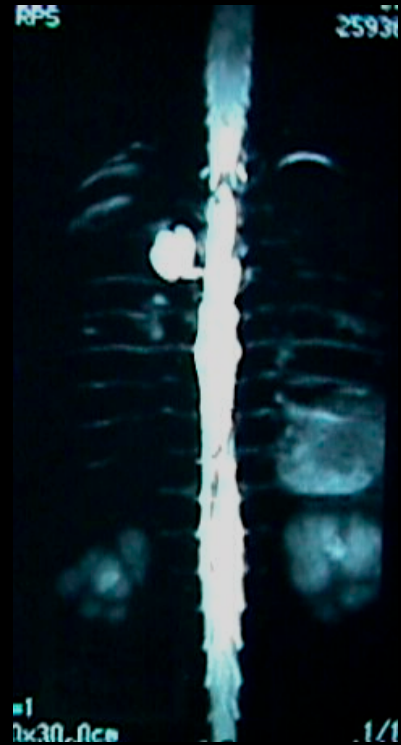
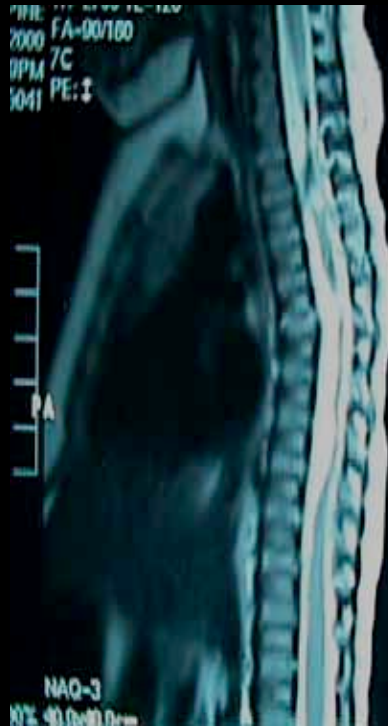Spinal Infection (Tuberculosis)

- The degree of compression by gibbous formation or epidural mass can be evaluated.
- Extent of Para-vertebral and epidural mass can also be studied on MR myelogram.



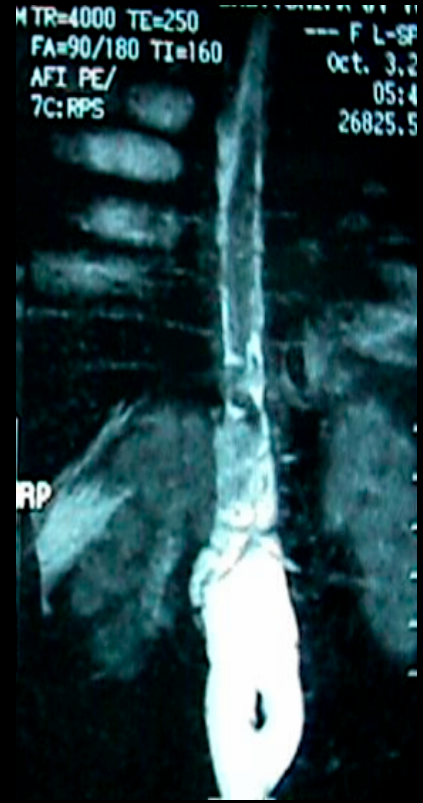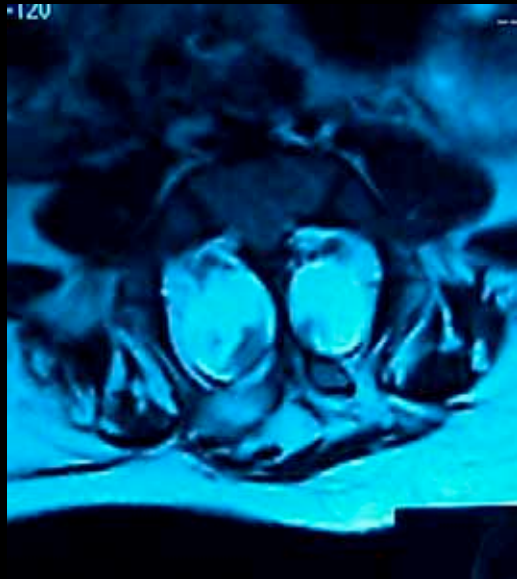Spinal Trauma.

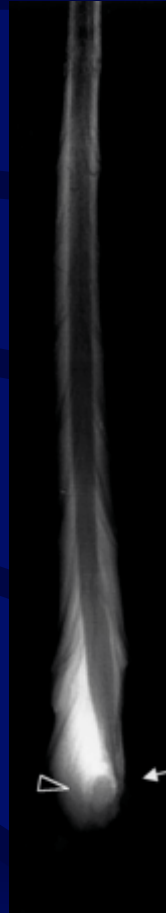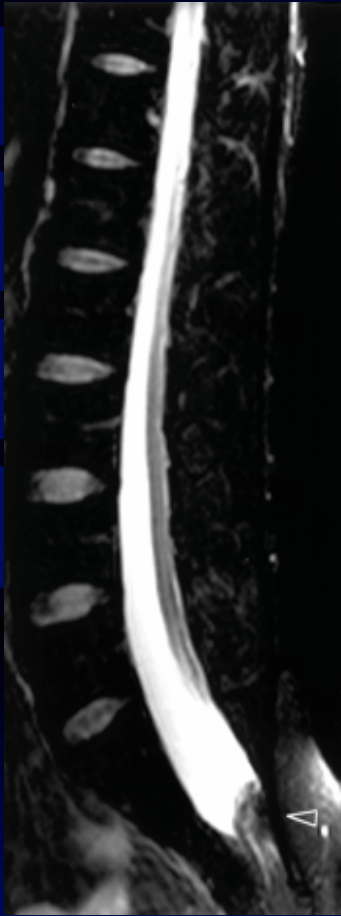
- Pressure on the thecal sac, traumatic disc herniation and filling defect due to presence of bony fragments can be seen.
- Traumatic meningocele Post traumatic cord cysts can be seen on MRM.



Congenital Anomalies

- Meningocele and myelomeningocele.
- Diastomatomyelia.
- Chiari Malformation.





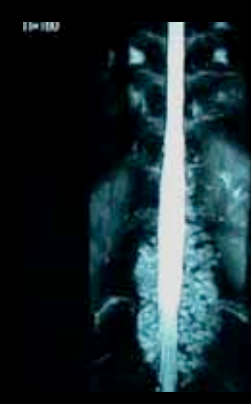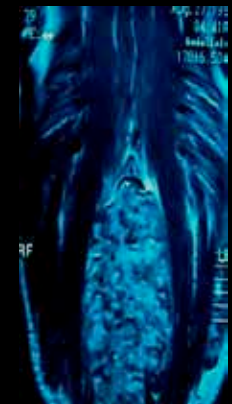
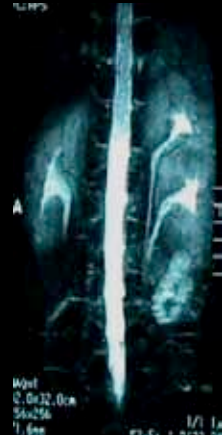
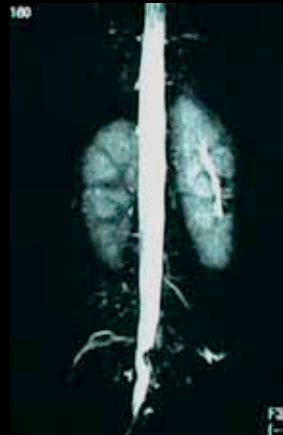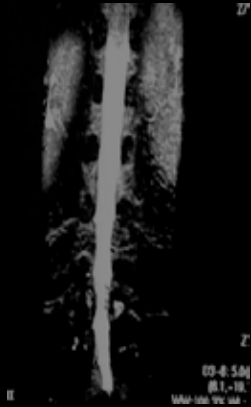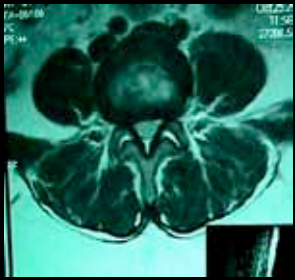Pitfalls in Imaging.

- Excessive extension of cervical spine may over-estimate the thecal pressure.
- If the maximum intensity projection of the thecal sac ends at L5 level, then a protruding disk at L5S1 may not be seen on MR myelogram images.

Disk protrusions seen on MRI may not be seen on MR myelogram if they only displace the epidural fat but not the thecal sac.

(M.J Thronton et al. Eur. Radiol 9, 924 - 929 (1999))

Incidental Findings



Conclusion

- MR myelography is a new, non invasive method that produces images comparable to conventional myelography. It is patient friendly, has no risk of side effects and because of its brief measurement time can be added routine imaging sequences.
- When used with MRI it can provide accurate diagnosis in evaluation of the majority of spinal pathologies.