



Developmental Dysplasia of the Hip: Beyond the Clinical Diagnosis

Tanya L. Tivorsak, B.A., Kalpesh Patel, M.D.,
Kimberly Carney, M.D., Nina B. Klionsky, M.D.,
Gary B. Tebor, M.D., Johnny U.V. Monu, M.D.




University of Rochester School of Medicine,
Departments of Imaging Sciences and Orthopedics,
Rochester, NY, United States


Objectives



- Review the spectrum of DDH
- Learn the current imaging criteria
- What the surgeon needs to know from the images
- Compare DDH versus hip dysplasia/dislocation in congenital disorders
- Current management options

Introduction






Definition


- Formerly known as congenital dislocation of the hip joint – but term changed since DDH is a developmental process and is not always detectable at birth.
- The term *dysplasia* tends to be used for hips with a positive Ortolani sign (hip that can be dislocated or a dislocated hip that is able to be relocated).
- The term *dislocation* tends to be used for hips with a negative Ortolani sign (unreducible hip).

Wide Spectrum of Conditions




- (1) Primary dysplasia without instability
- (2) Instability (subluxable and dislocatable)
- (3) Subluxed
- (4) Dislocated

Wide Spectrum of Conditions




- Teratologic hip conditions are considered a different entity from DDH. They arise earlier in fetal development and are associated with other malformations.
- However, there is conflicting literature in whether teratologic hips are part of the DDH spectrum or not.



Etiology


- **Multifactorial** – genetic + intrauterine environmental factors
- **Usually unilateral** (80% of the time), occurs **more frequently in the left hip** – since the left hip of the fetus usually lies posteriorly against the mother's L-spine, limiting abduction



Risk Factors

- Native-Americans
- Family history
- Females
- Breech delivery
- Oligohydramnios
- First born
- Persistent hip asymmetry


Embryology – Periods of Risk for Hip Dysplasia



After last menstrual period in fetal development:

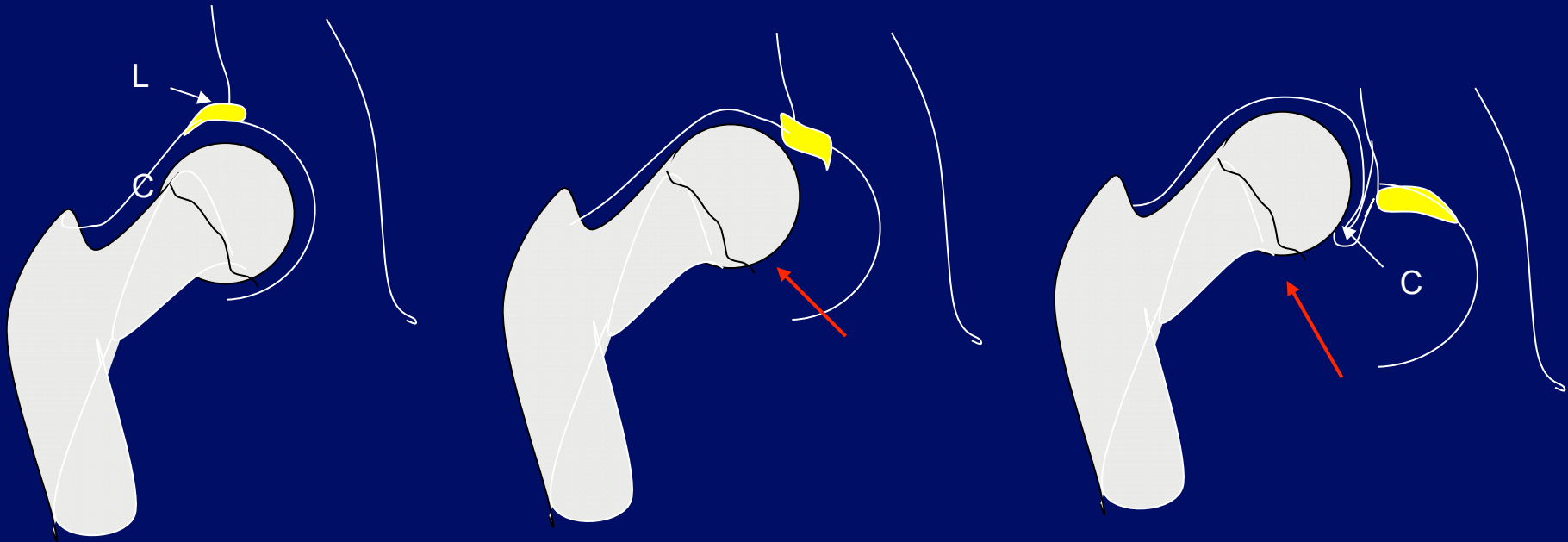

- 12 weeks – lower limb rotates medially after hip joint arises at 7-11 wks – **dysplasias are teratologic**
- 18 weeks – hip muscle development – **dysplasias due to neuromuscular disorders**
- Between perinatal period and 1st few weeks of birth – femoral head grows faster than acetabulum, minimal coverage of head – **dysplasias due to mechanical factors - oligohydramnios, breech position**
- Postnatal period – labral growth more rapid (more coverage of femoral head) – **dysplasias tend to be due to functional factors instead – increased estrogens causing ligamentous laxity, swaddling**

Natural History



- Loss of tight fit between acetabulum and femoral head in the hip → may result in dysplasia or dislocation
- Findings – shallow acetabulum with femoral anteversion

Natural History




Normal Hip –
labrum is everted

Subluxed Hip – some
inversion of labrum

Dislocated Hip – inversion of
labrum, which becomes
hypertrophied → called
“limbus,” which may prevent
hip reduction


L = Labrum, C = Capsule



Complications – If Untreated

- Pain
- Early osteoarthritis
- Limb length discrepancy
- Decreased agility
- Abnormal gait/limping

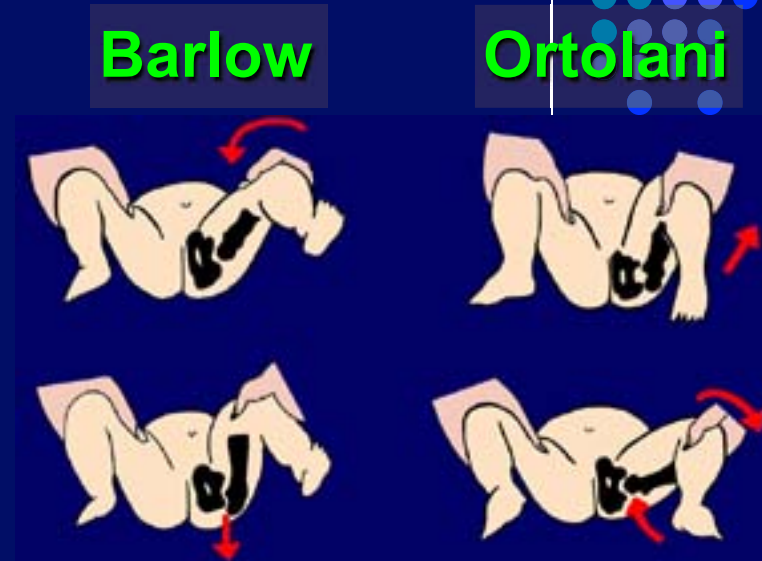
Clinical Diagnosis






Clinical Diagnosis

- Ortolani's (reduction) and Barlow's (dislocation) maneuver
- Shortened leg with limited abduction when flexed (6-8 wks of age)
- Asymmetry of thigh folds (rare)
- Galeazzi's sign (6-8 wks) - uneven knee levels when the supine infant's feet are placed together on the exam table with the hips/knees flexed usually seen in unilateral DDH.




Clinical Diagnosis




- If hip dysplasia or dislocation is suspected, the patient should be examined to rule out any underlying medical or neuromuscular disorder.


Recommendations for screening



Abnormal exam	Refer to orthopedist
Inconclusive exam (i.e. hip click that seems benign/uncertain)	Do follow-up exam in 2 wks – if the exam is positive or still inconclusive, refer to orthopedist and recommend US
Negative exam + risk factors	Recommend imaging at 4-6 wks

Imaging in DDH







Imaging Modalities in DDH

- **Ultrasound** – for screening, useful in neonatal period
- **Radiographs** – useful after the femoral head starts to ossify (3-4 months of age)
- **MRI** – evaluation of difficult cases and complications of DDH
- **CT** – most commonly used post-treatment to view reduction

Ultrasonography



- Dynamic Standard Minimum Examination –
 1. **Static** (Graf method) assessment in coronal plane with the hip at rest, based on shape and depth of acetabulum by morphology and angular measurements
 2. **Dynamic** (Harcke method) assessment in transverse plane with the hip under stress

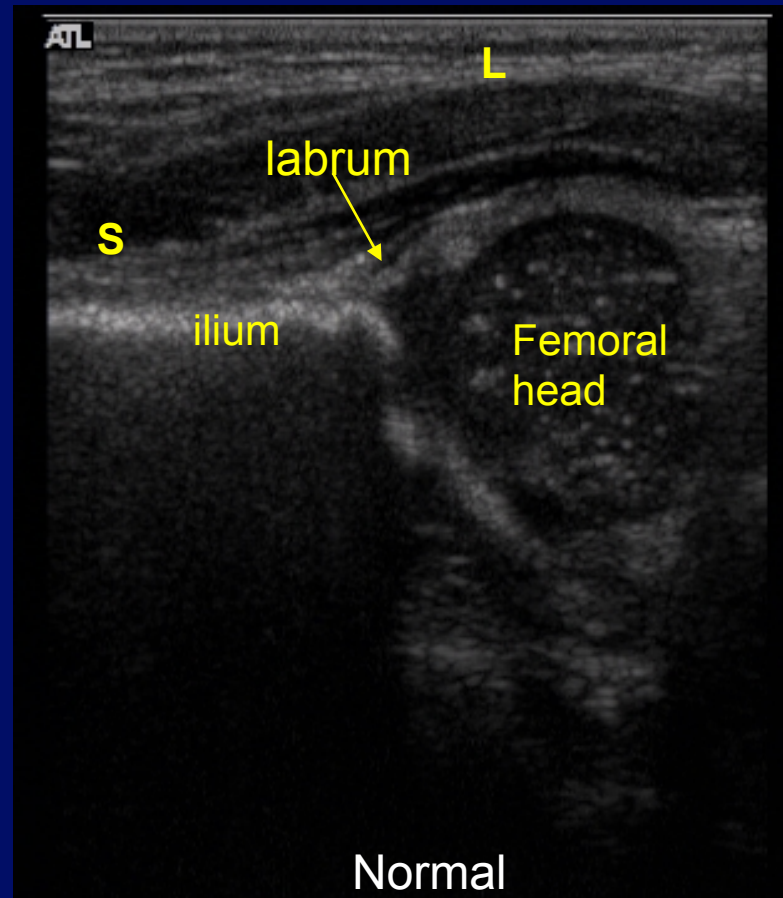


Static

Coronal view – hip at rest

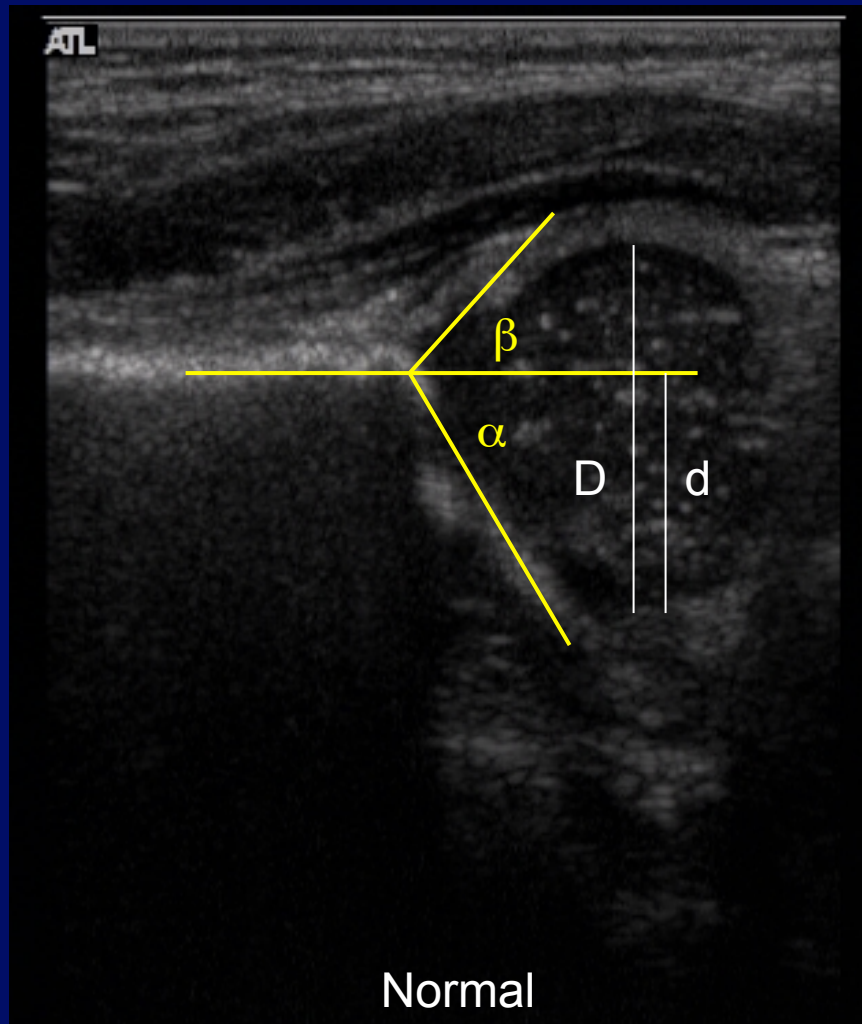

S = superior

L = lateral



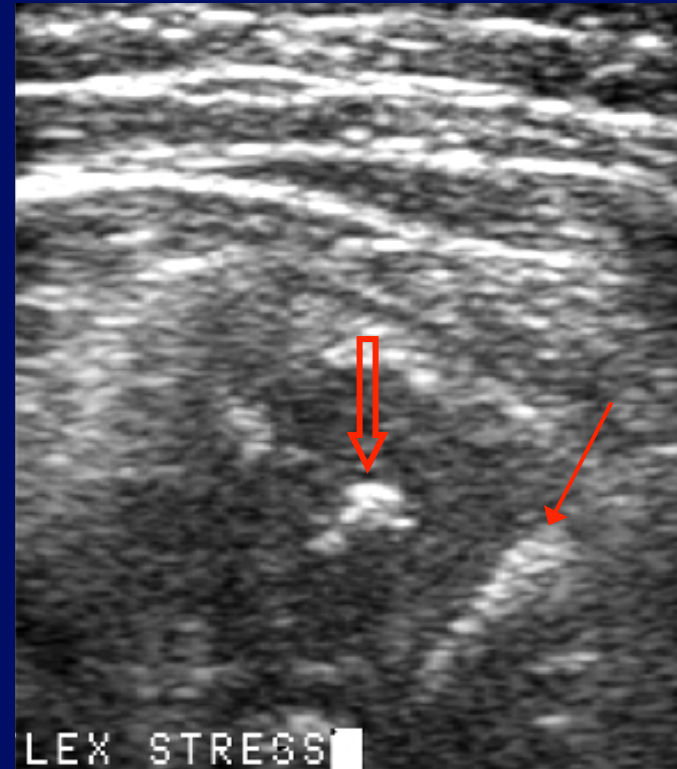
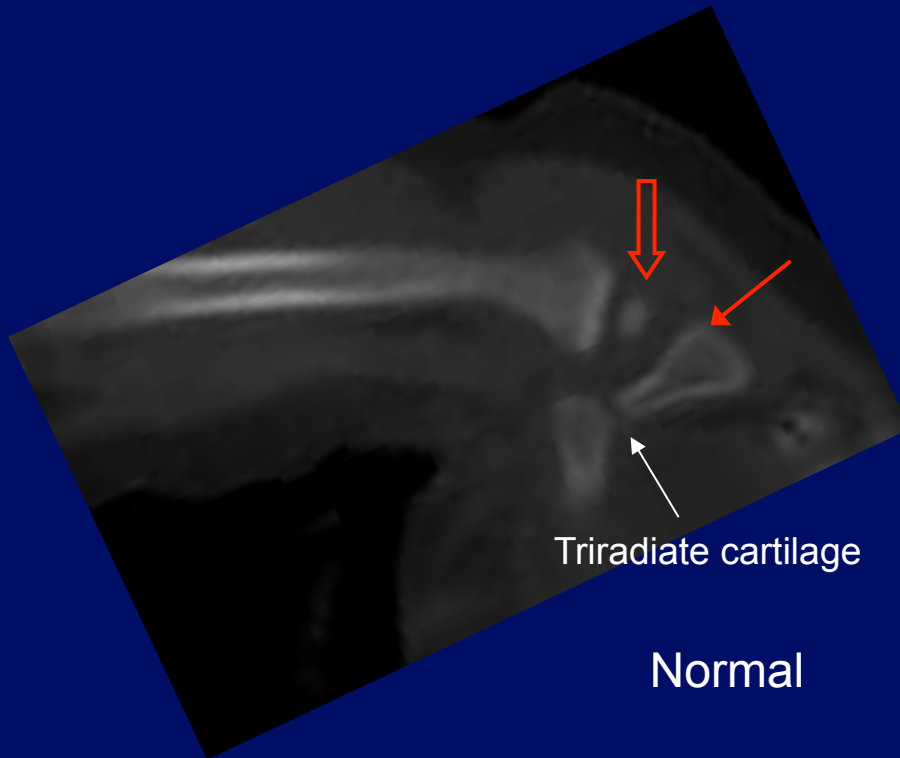

To get this view – the transducer is placed in coronal orientation over the lateral aspect of the hip, with the infant supine or in the lateral decubitus position.

Normal Graf Measurements



- α angle (normal = $> 60^\circ$) indicates angle of bony acetabulum.
- β angle (normal = $< 55^\circ$), indicates angle of cartilaginous femoral head coverage.
- Femoral head coverage by acetabulum – normal ratio of d/D is $> 50\%$.


Dynamic



Axial/transverse flex stress view on US: Femoral head ossification visualized (**open arrow**) with ischium (**thin arrow**). Compare anatomy with CT (similar positioning). This hip was nonsubluxable. If the hip subluxes posteriorly on this view, it is abnormal.


To get this view: Place U/S transducer over femoral head transverse to pelvis, flex hip, and exert posterior stress on knee.

Graf vs Harcke Classification




- **Harcke's methods** are more equivocal for evaluation since they depend on hip stability tests – many DDH cases may not yield positive results in Harcke's test (i.e. not sublutable).
- **Graf's classification** gives a better indication of the normal and dysplastic conditions.

U/S Graf classification**

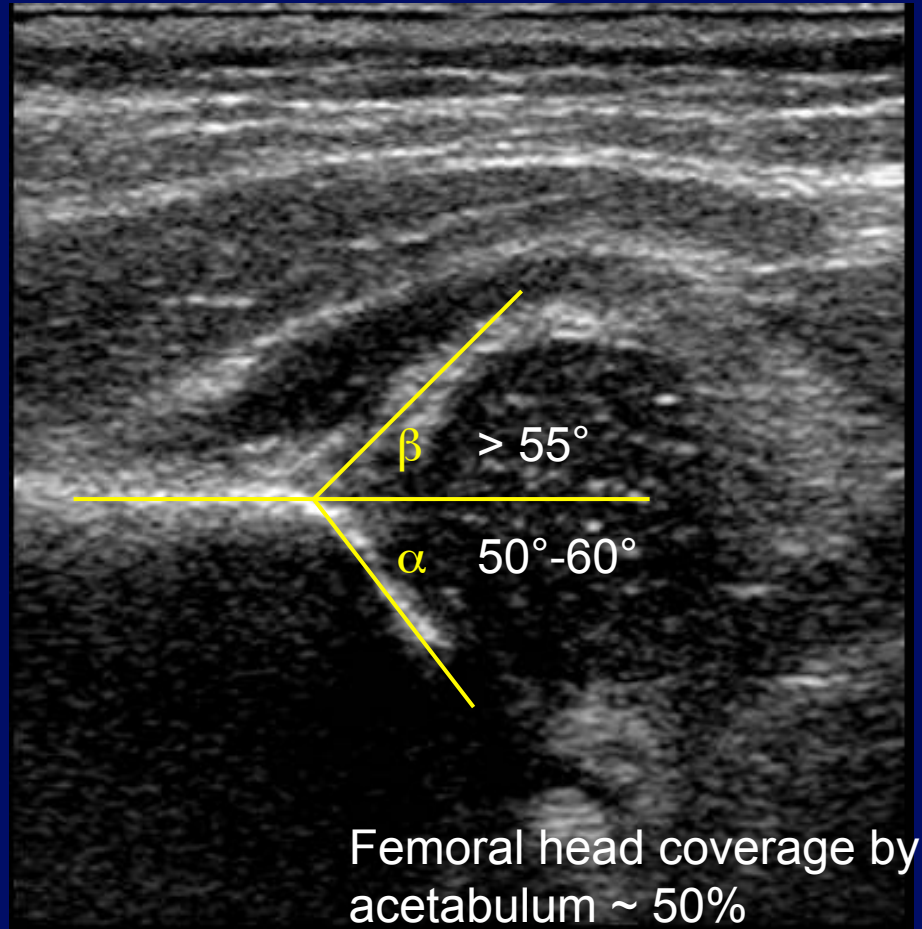


Class	Features	Treatment
I - mature	Good bony modeling, α angle $> 60^\circ$	None
Ila(+) -physiologic immaturity	Satisfactory bony modeling, α angle = $50^\circ - 59^\circ$	Follow-up, no Tx
Ila(-) – maturational deficit < 3 mo old	<ul style="list-style-type: none"> α angle = $50^\circ - 59^\circ$, β Angle $< 55^\circ$ Deficient bony modeling Cartilaginous acetabular roof is still broad and covers femoral head 	Pavlik harness or if borderline - just follow-up
Ilb – delayed osseous development > 3 mo	-----Same as Ila(-)-----	Pavlik harness
Ilc – critical zone hip Ild – decentering hip	<ul style="list-style-type: none"> α angle $43^\circ - 49^\circ$, β Angle $< 77^\circ$ in Ilc, $> 77^\circ$ in Ild Deficient/highly deficient bony modeling Cartilaginous acetabular roof is still broad 	Pavlik harness
IIla, IIlb, IV – Eccentric hip	<ul style="list-style-type: none"> α angle $< 43^\circ$, β Angle $> 77^\circ$ Poor bony modeling, flattened bony promontory Displaced cartilage roof triangle 	Pavlik ($> 95\%$ successful in IIIa/b, 50% successful in IV), possible reduction

**Classification does not take into account the position of the femoral head.

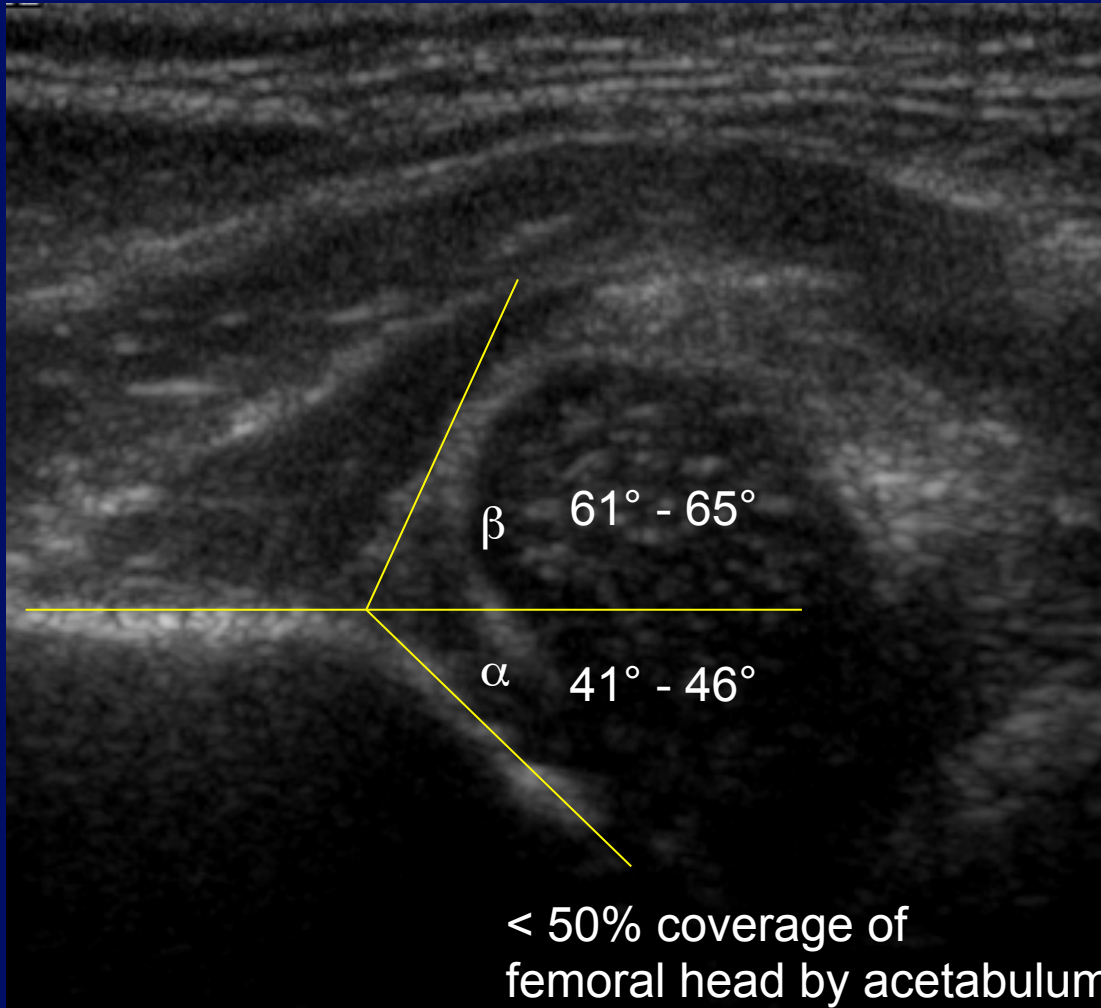



Graf IIa – 3 week old female with FHx of DDH



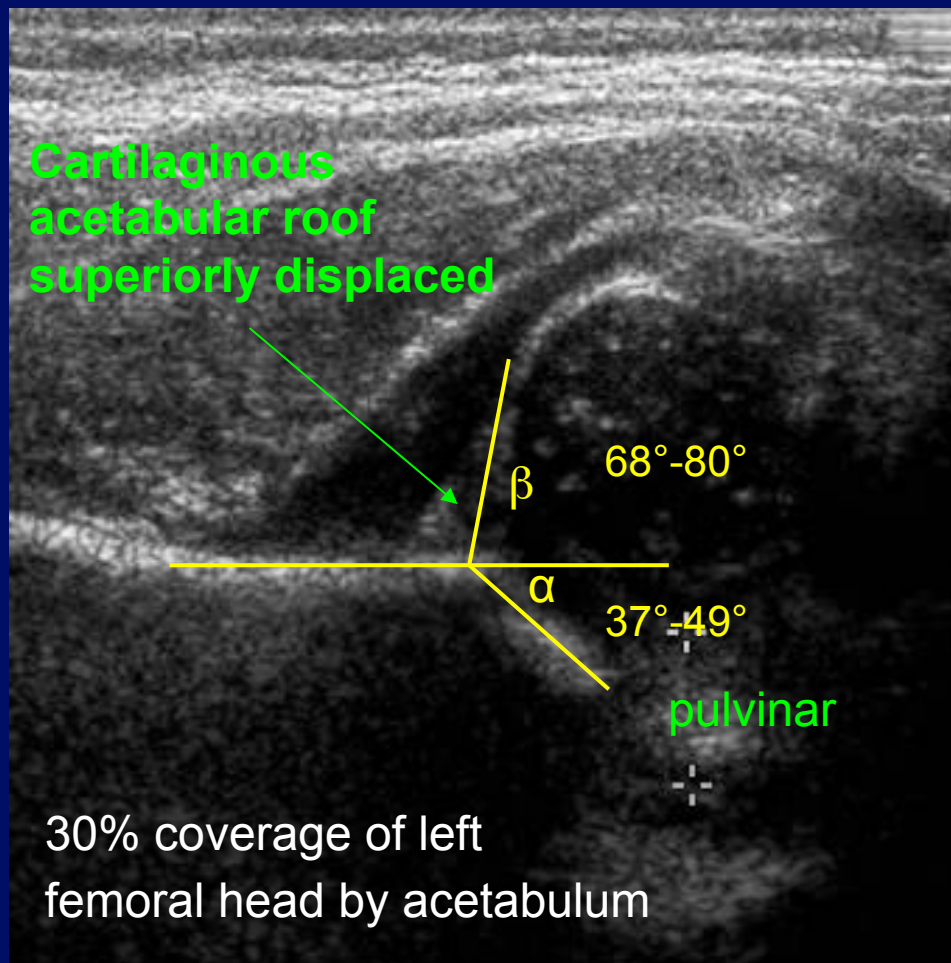
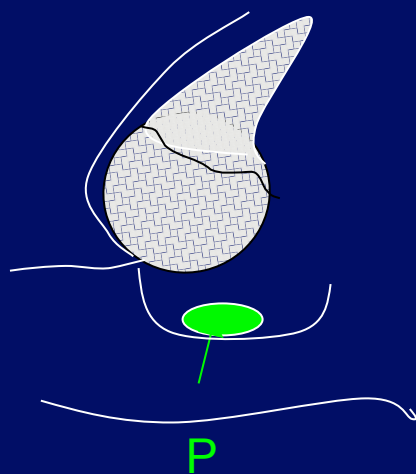

IIa – Physiologic Immaturity

Graf IIc – 3 week old with hip click




Lateral and superior displacement of femoral head

Graf III: 2 day-old female with high risk FHx (mother, sister with severe hip dysplasia) and negative Ortolani and Barlow's tests (dislocated hip unable to be reduced)



Pulvinar (P) = fibrofatty tissue between acetabulum and femoral head, more evident in DDH due to femoral head not pressing against it in the acetabulum.

Pelvic Radiographs




- Views - supine frontal or standing frontal (older children)

USEFUL FOR:


- After 3-6 mo of age – femoral head ossification visible
- Evaluating abnormalities of lower L-spine, sacrum, proximal femur
- Assessment of hip flexion in Pavlik harness placement in infants
- Maintenance of reduction
- Track resolution of acetabular dysplasia
- Monitor for AVN

Reliable Radiographic Parameters



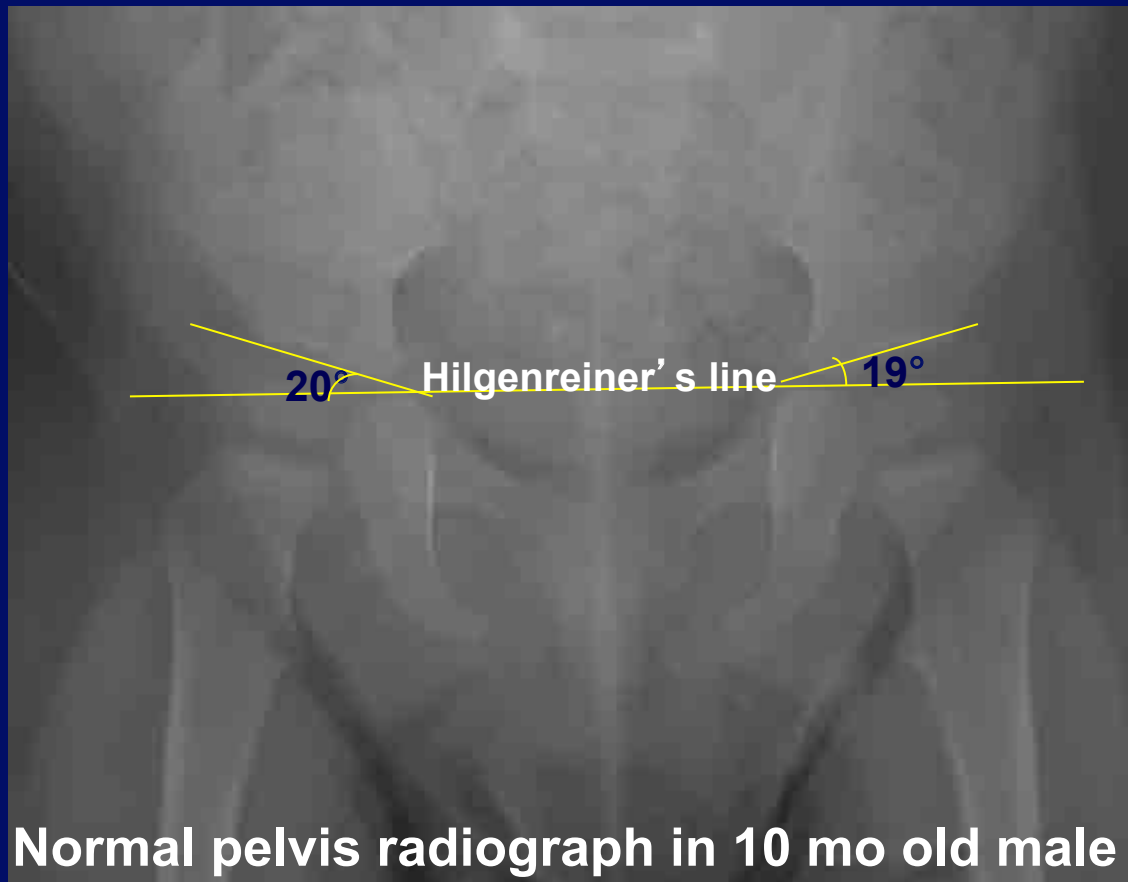
1. **Acetabular Angle** (useful for assessment of resolution)
2. **Femoral head position** with reference to Hilgenreiner's and Perkin's (H and P) lines
3. **Shenton's arc**
4. **Center-edge angle** (Wiberg and Ogata)

These parameters are useful to the orthopedic surgeon in evaluating DDH.




Acetabular Angle

- Angle between Hilgenreiner's line (line through triradiate cartilages) and line through the superior acetabular roof




Acetabular Angle – Normal Values



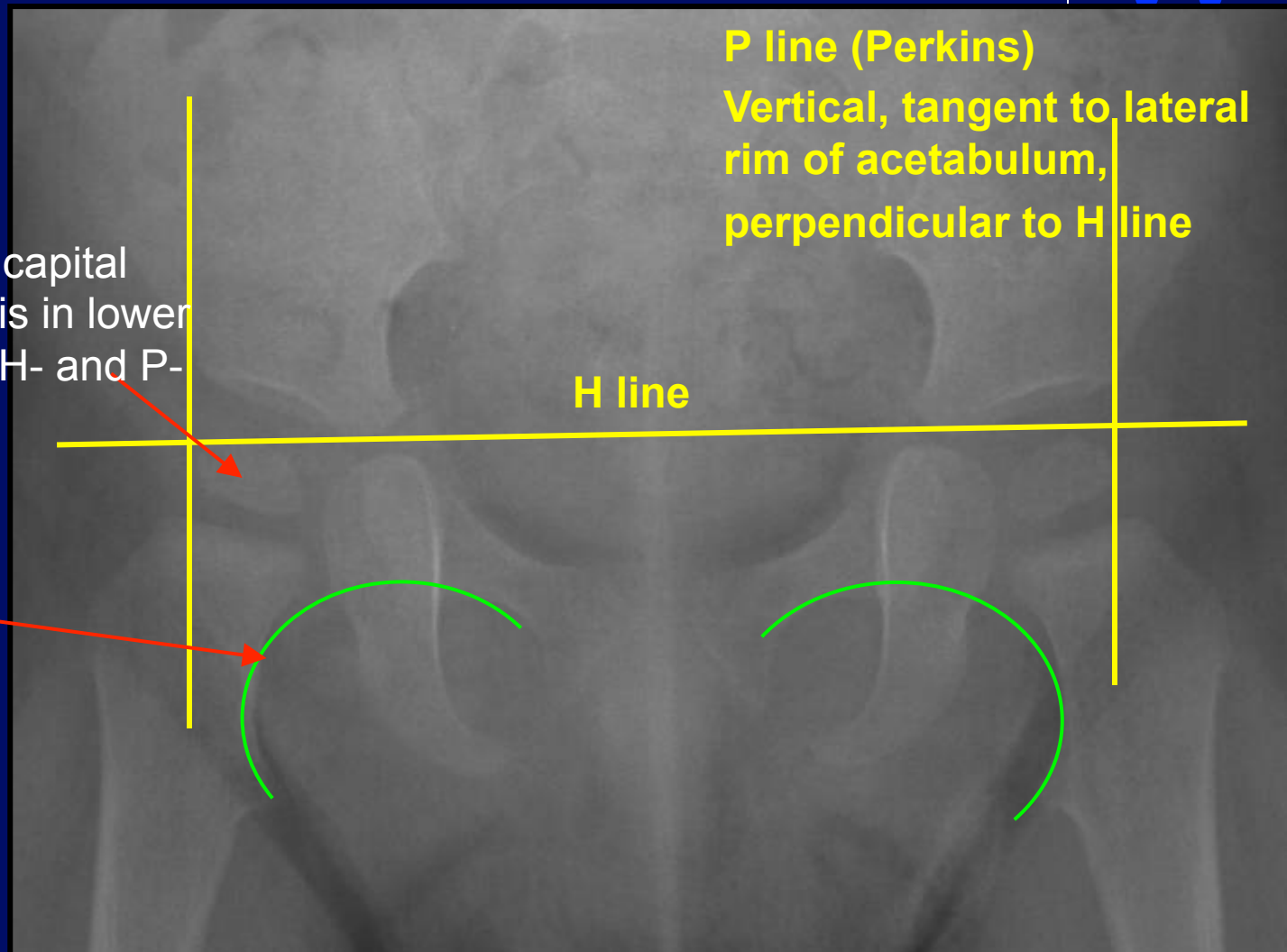
- < Age 2: $17^{\circ} - 30^{\circ}$
- > Age 2: $18^{\circ} \pm 4^{\circ}$
- Angle decreases with age due to modeling of the acetabulum by the femoral head and/or bone maturation along the acetabular roof.

Femoral Head Position and Shenton's Arc



1) Normal ossified capital femoral epiphysis in lower inner quadrant (H- and P-lines)

2) Shenton's arc




P line (Perkins)
Vertical, tangent to lateral rim of acetabulum, perpendicular to H line

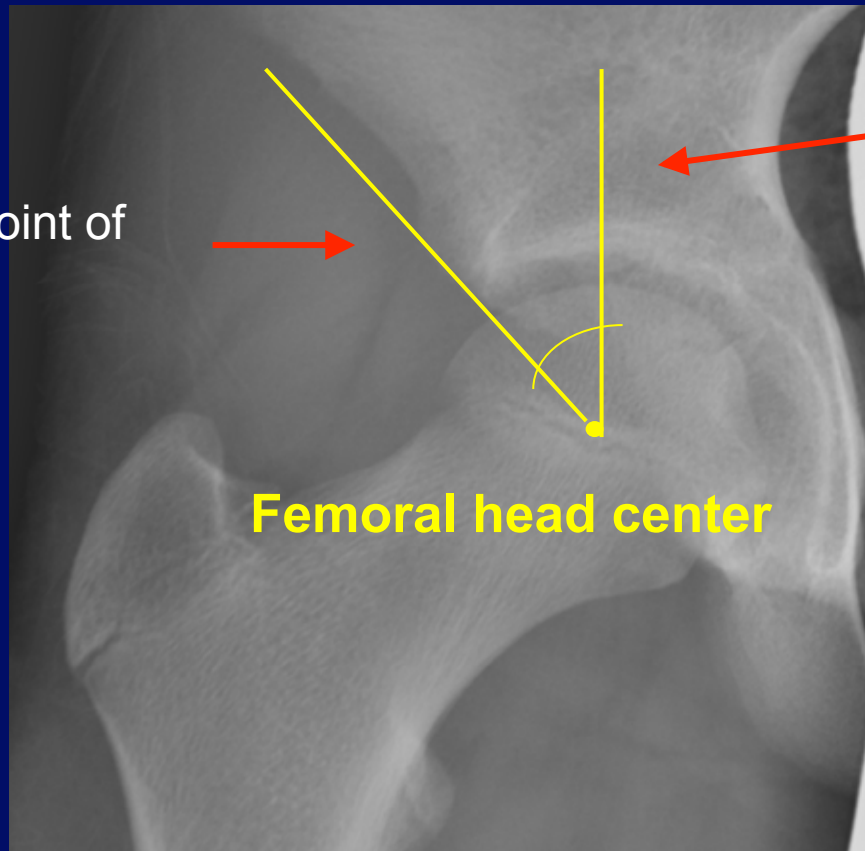
H line

Normal Hip Radiograph

Center-Edge (CE) Angle of Wiberg



Line to most lateral point of acetabular roof




Line parallel to longitudinal body axis


Femoral head center

Quantitates lateral coverage of femoral head by the acetabulum

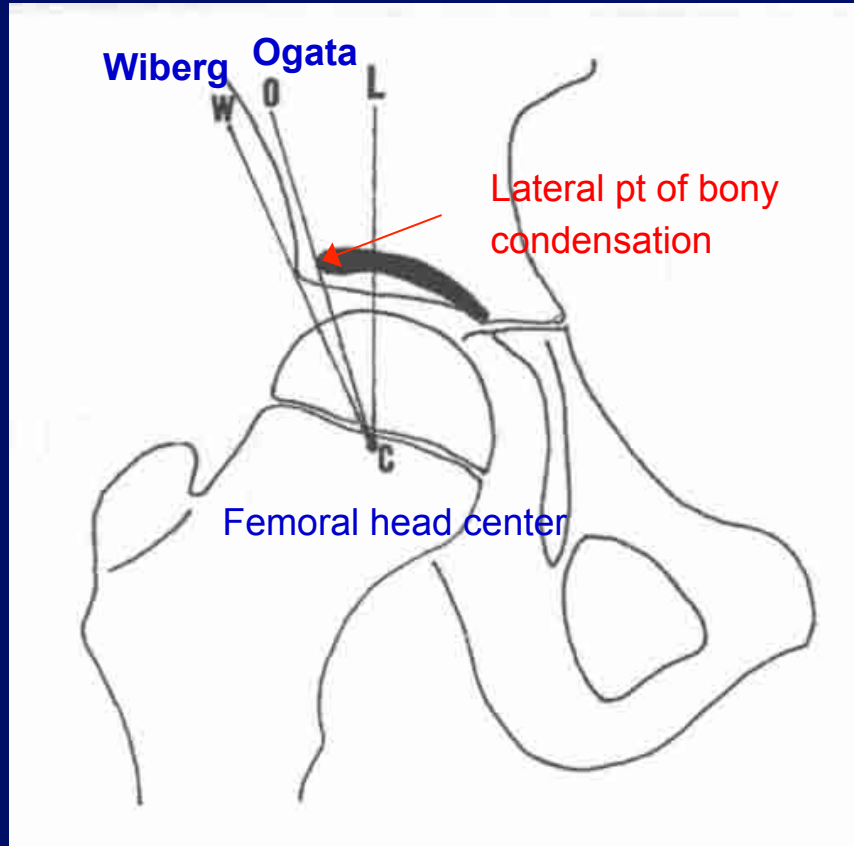
Center-edge (CE) angle of Wiberg



- Normal values:
 - > 19° in 5-8 years
 - > 25° in 9-12 years
 - > 26°- 30° in 13-20 years
- **More reliable** in children **over age 5** since femoral head center is difficult to define in children under age 5



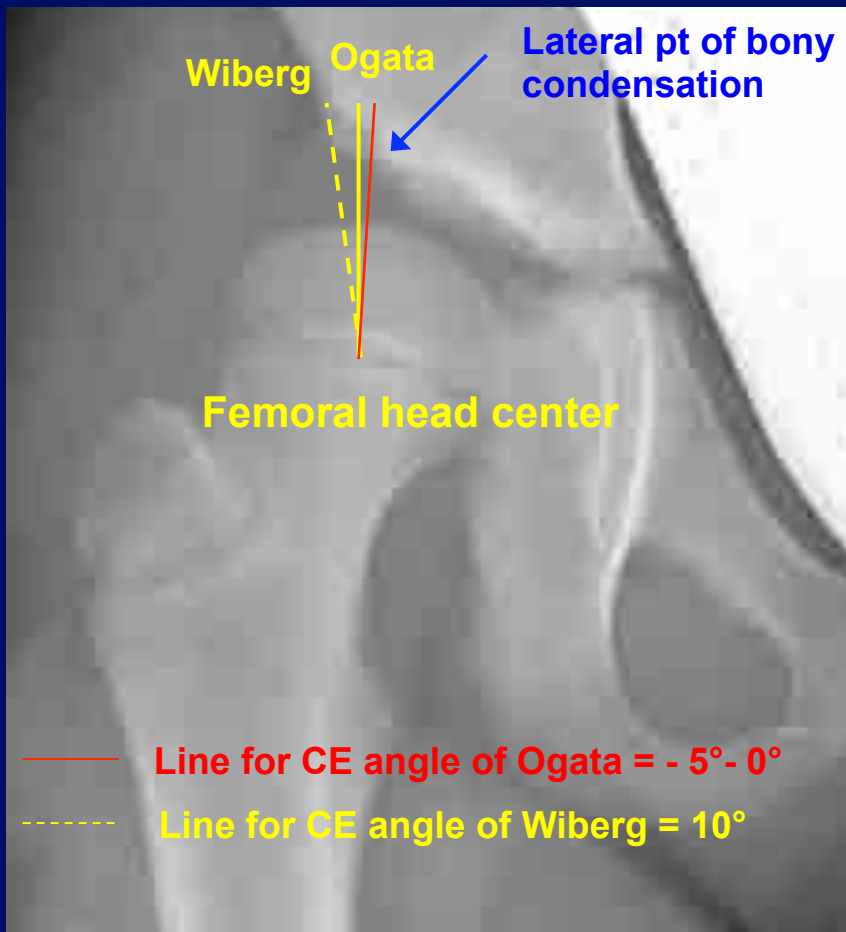

Refined CE Angle of Ogata



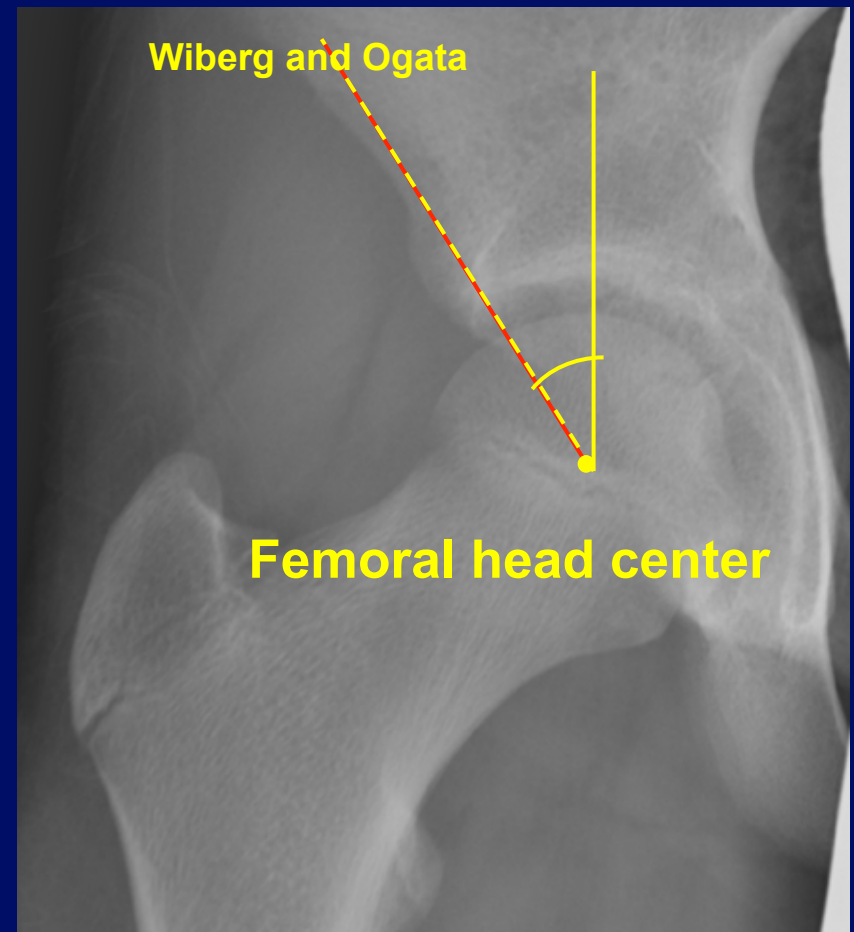
Similar to CE angle of Wiberg except the lateral line is tangent to the lateral point of bony condensation

Image modified from Omeroglu et al., 2002

Comparison of CE Angles in DDH vs. Normal Hip




DDH



Normal Hip

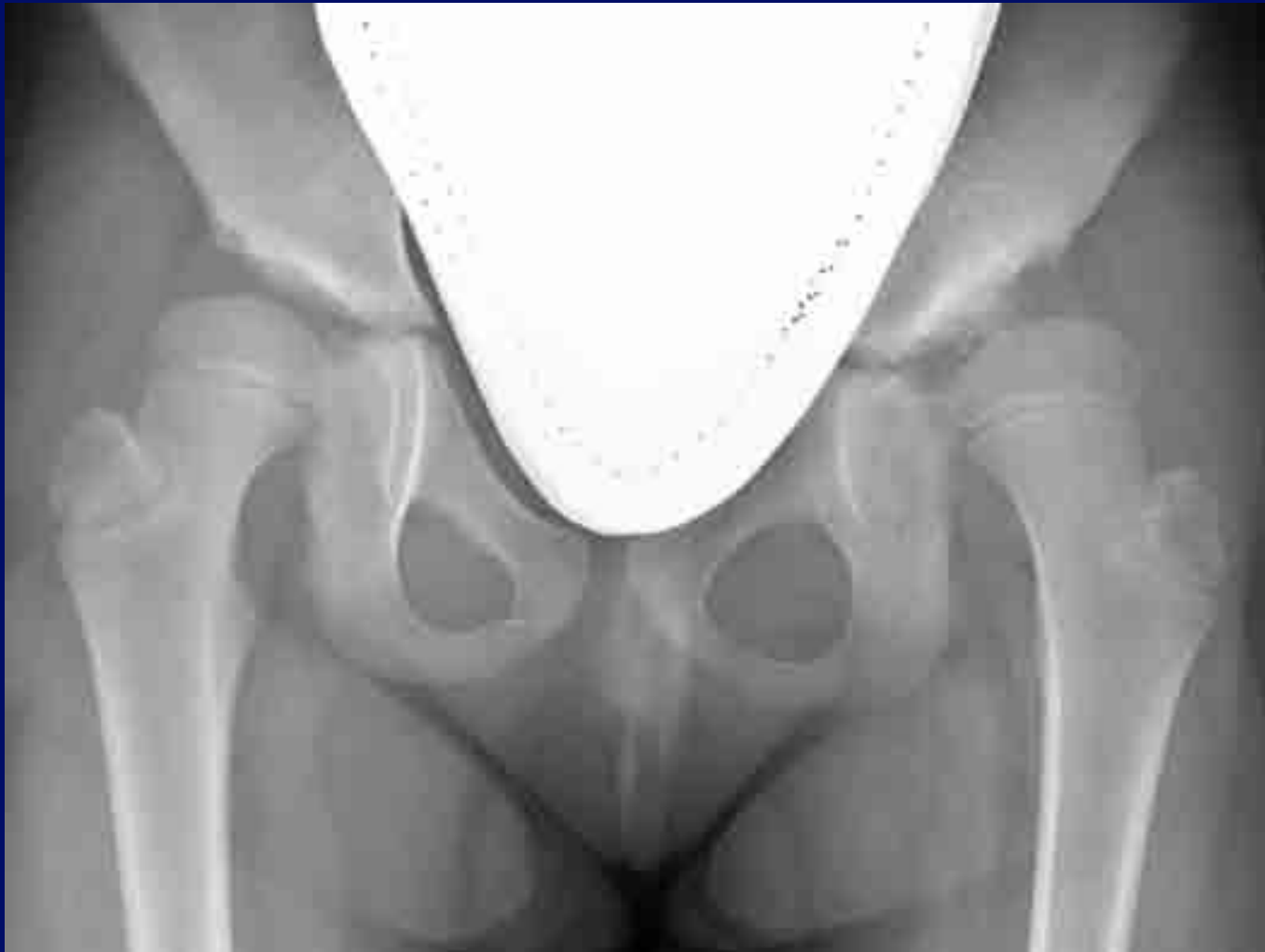
Refined CE Angle of Ogata



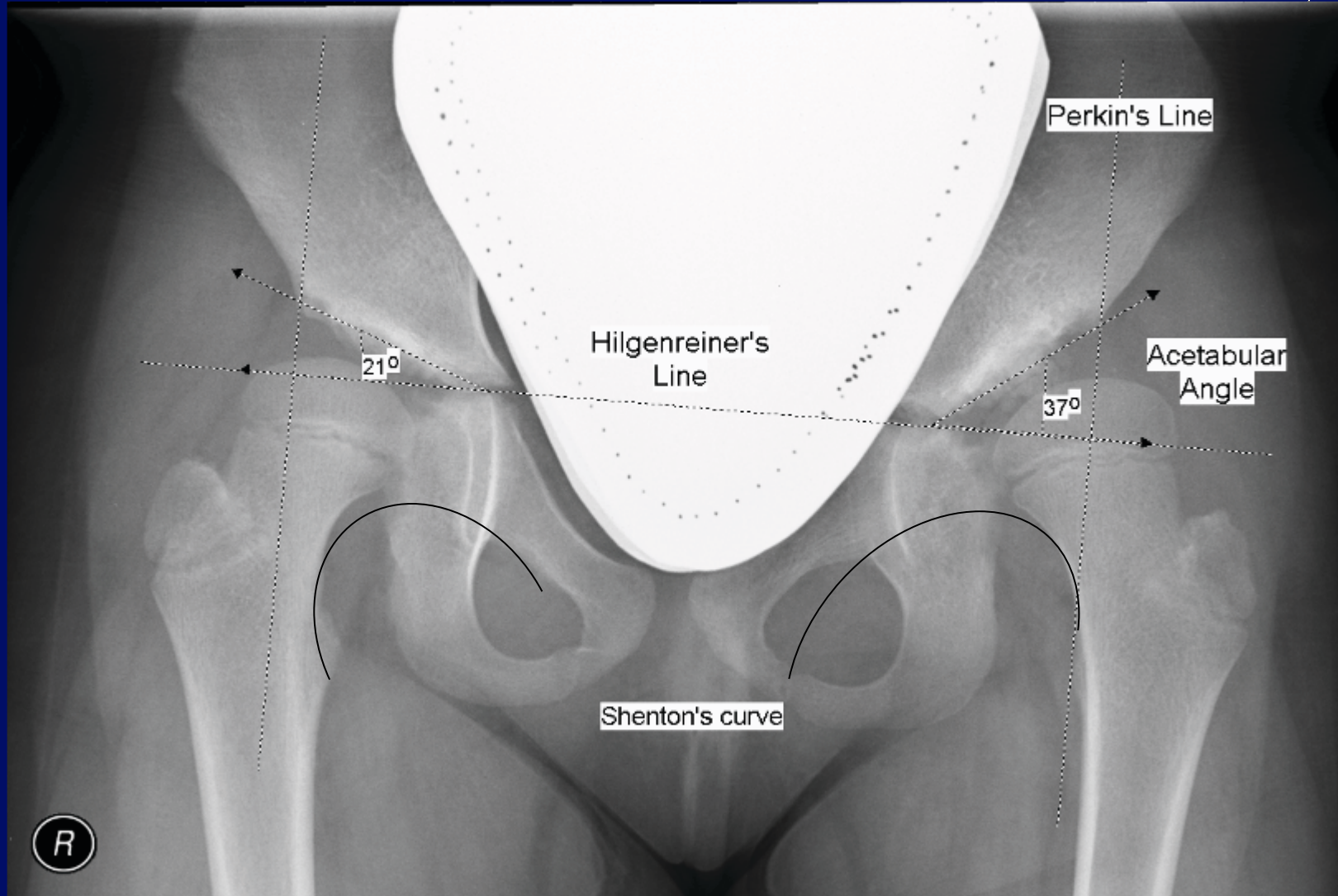

Problems with CE angle of Wiberg:

- May overestimate lateral femoral head coverage in severe cases.
- Subchondral bony condensation in acetabular roof represents magnitude of compressive stresses, not lateral point of acetabulum.
- A poor acetabular cover has shown to be present in hips with a normal CE angle of Wiberg but in which the lateral point of bony condensation is short of the lateral rim of acetabular roof.
- Refined CE angle of Ogata addresses these problems.

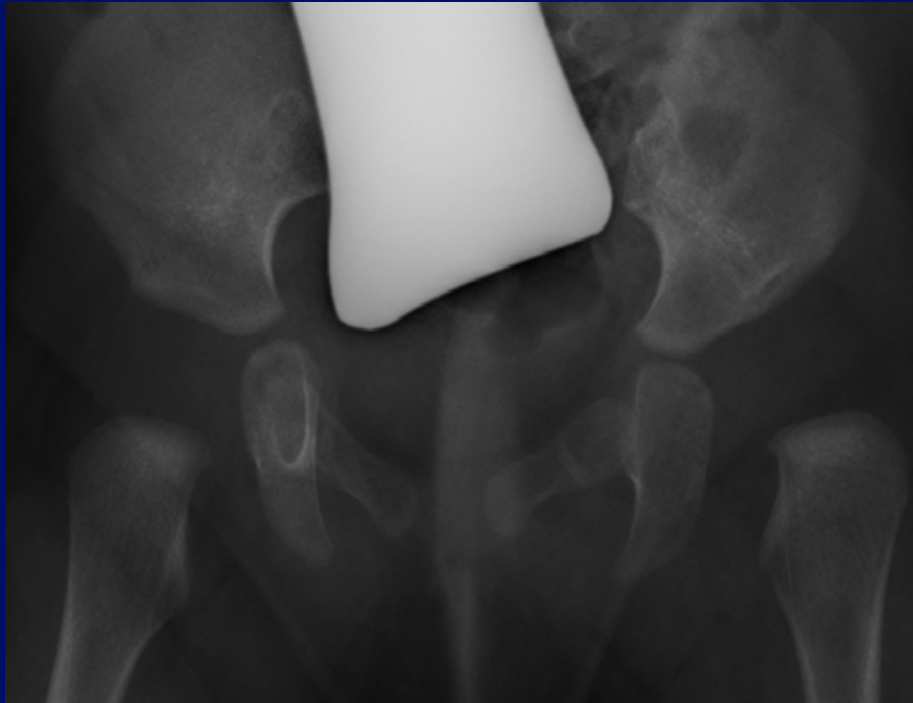
Radiograph: Late-diagnosed DDH in a 7 year-old female from Mexico



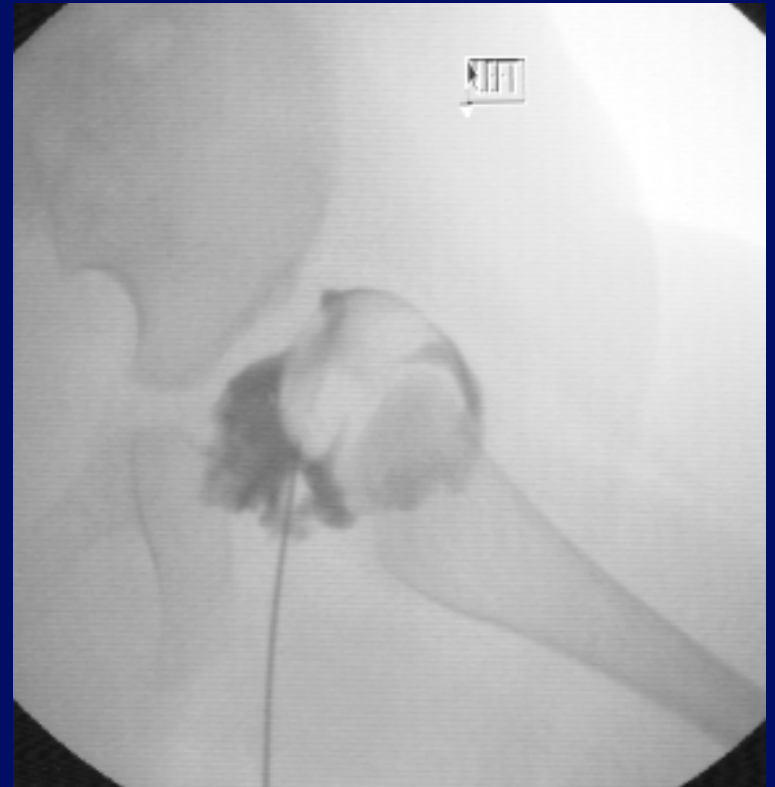
Radiograph: Late-diagnosed DDH in a 7 year-old female from Mexico



Arthrogram – 6 month-old female with left DDH




Left hip: Femur appears laterally displaced.




Left hip: Medial pooling of contrast in the joint space. The femoral head is subluxed superiorlaterally.

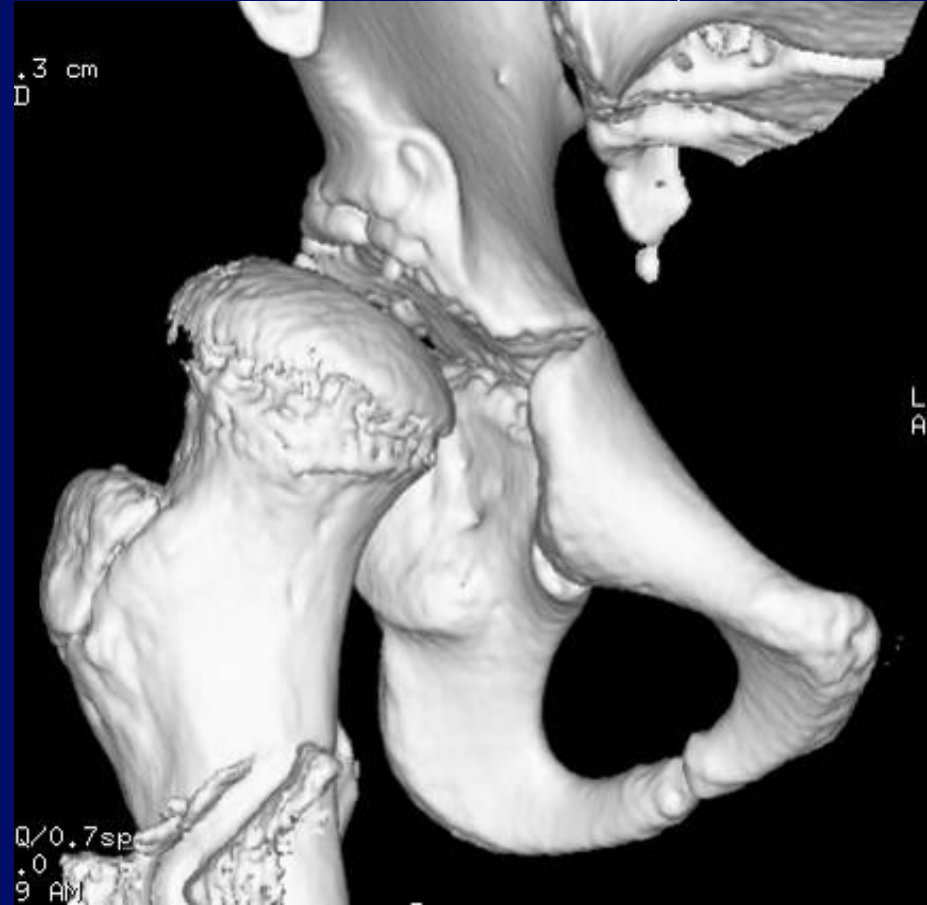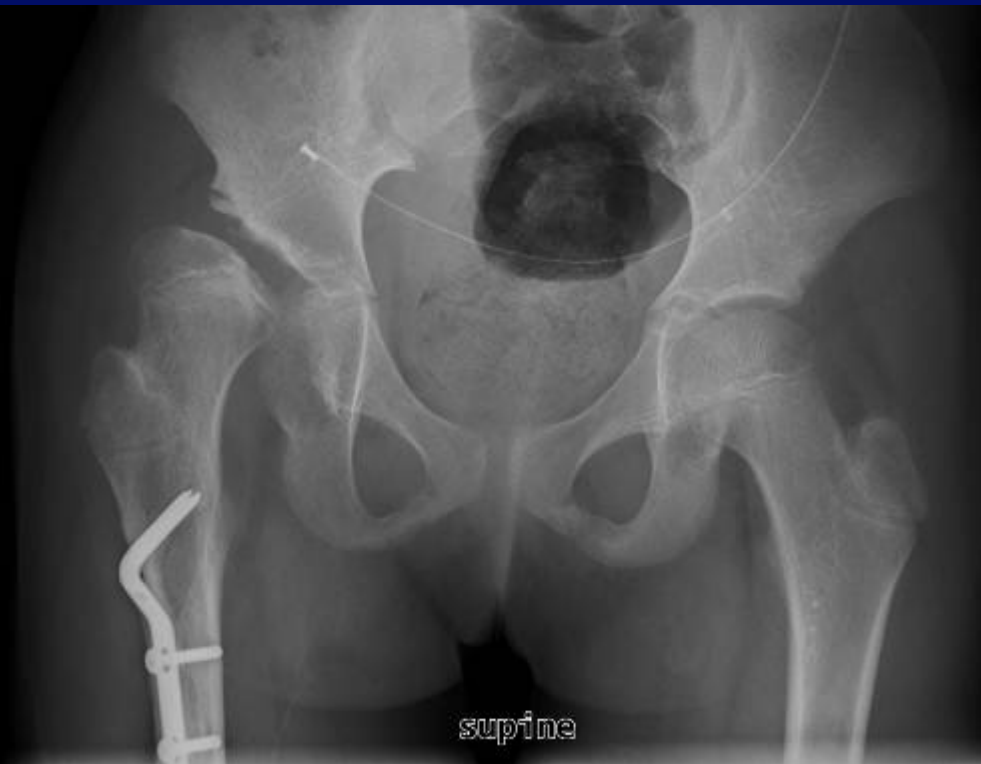CT



- Most commonly used to document reduction if child is placed in spica cast.
- Can be performed preoperatively in the older child in severe cases to help the surgeon in planning treatment procedures.
- Protocol = 0.75 – 1.5 mm collimation and 0.5 – 1.0 mm reconstructions, scan only through the hip joint.
- 3-D reconstruction for better hip analysis in complex cases and for preoperative planning.




CT reconstruction: Right hip dysplasia s/p varus osteotomy of proximal femur shaft



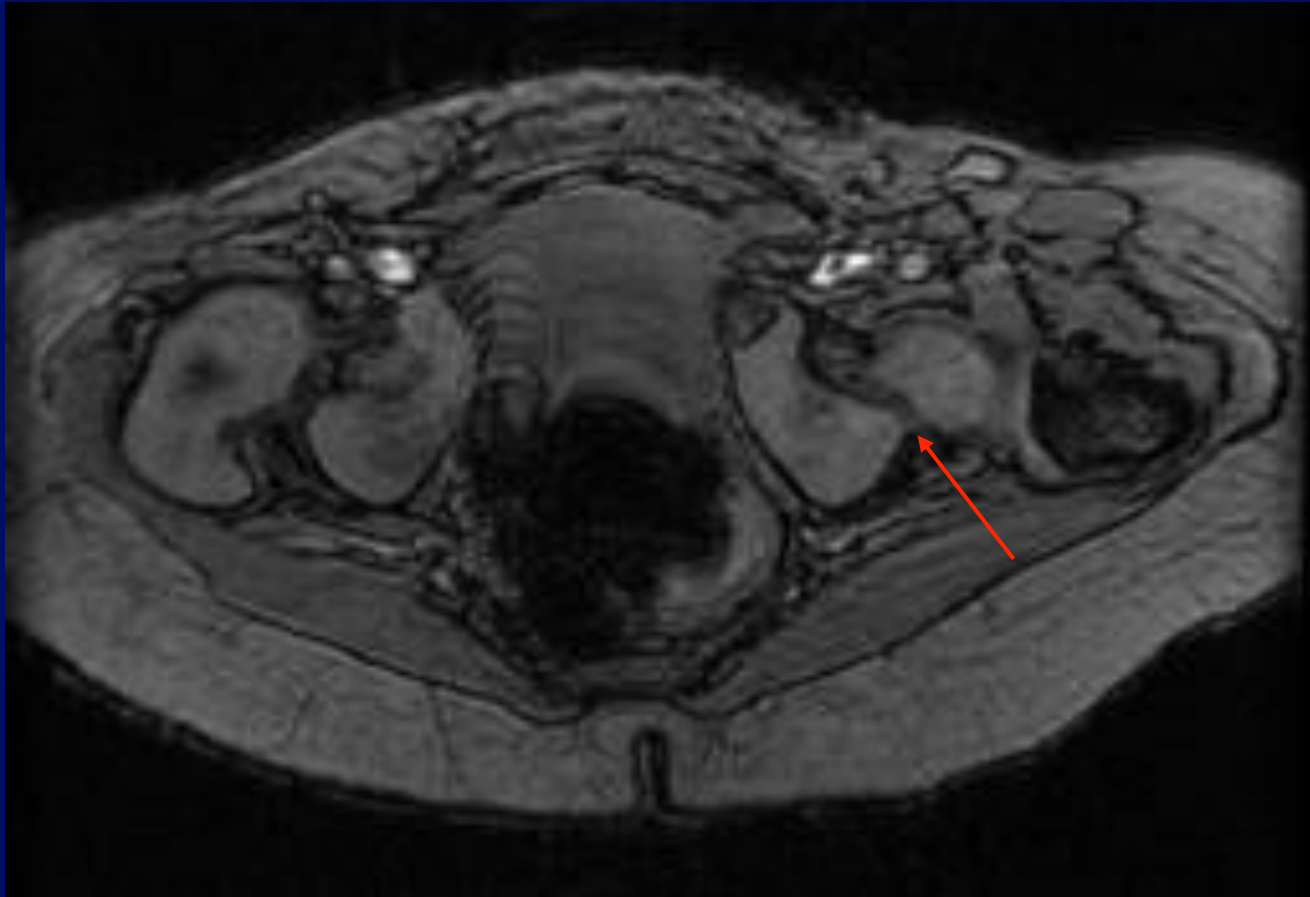

Flattened femoral head that is laterally subluxed, dysplastic and shallow acetabulum.

MRI



- Evaluation of difficult cases – if acetabular formation is inconclusive and subluxation still remains after conservative treatment.
- Evaluation of newborns with cartilaginous femoral heads (not ossified yet) in difficult cases.
- Evaluate treatment complications (i.e. AVN).

11 month old male with DDH

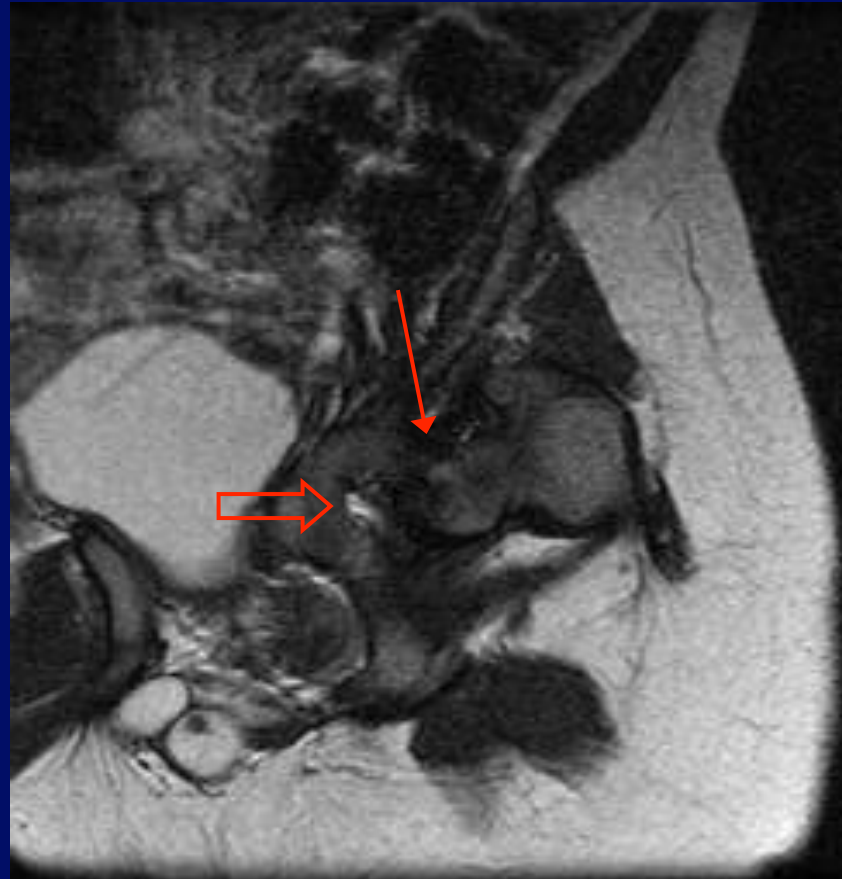



Axial Gradient Echo:

Left hip: High-riding femoral head (1) abuts posterior lip of acetabulum (arrow) and (2) is rotated and displaced posteriorlaterally.

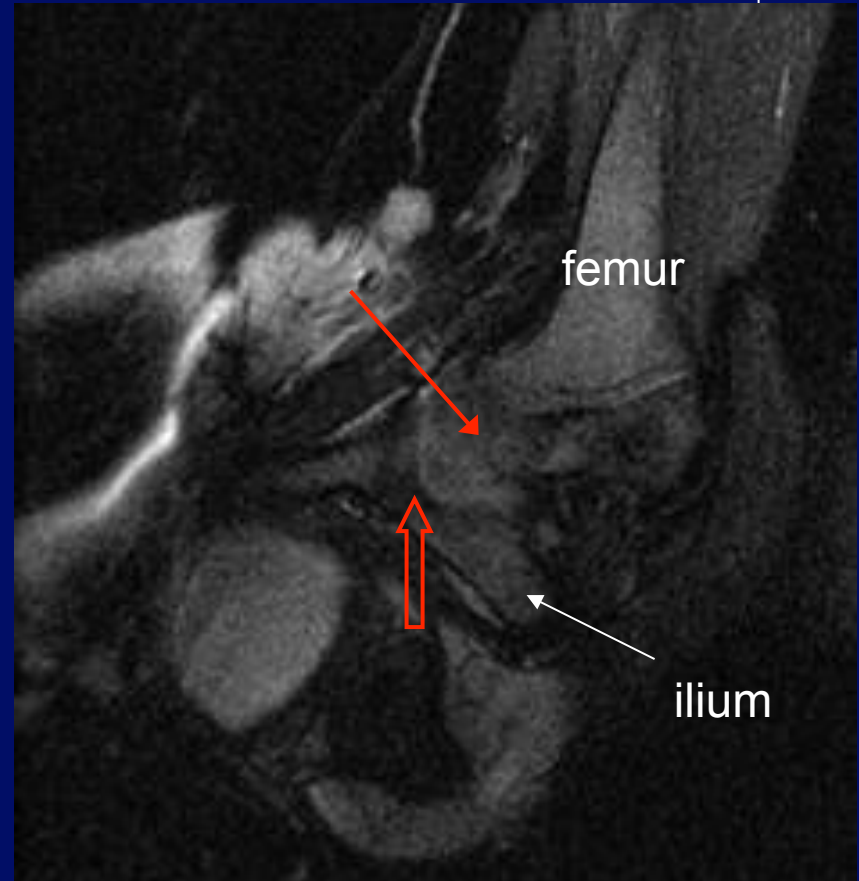
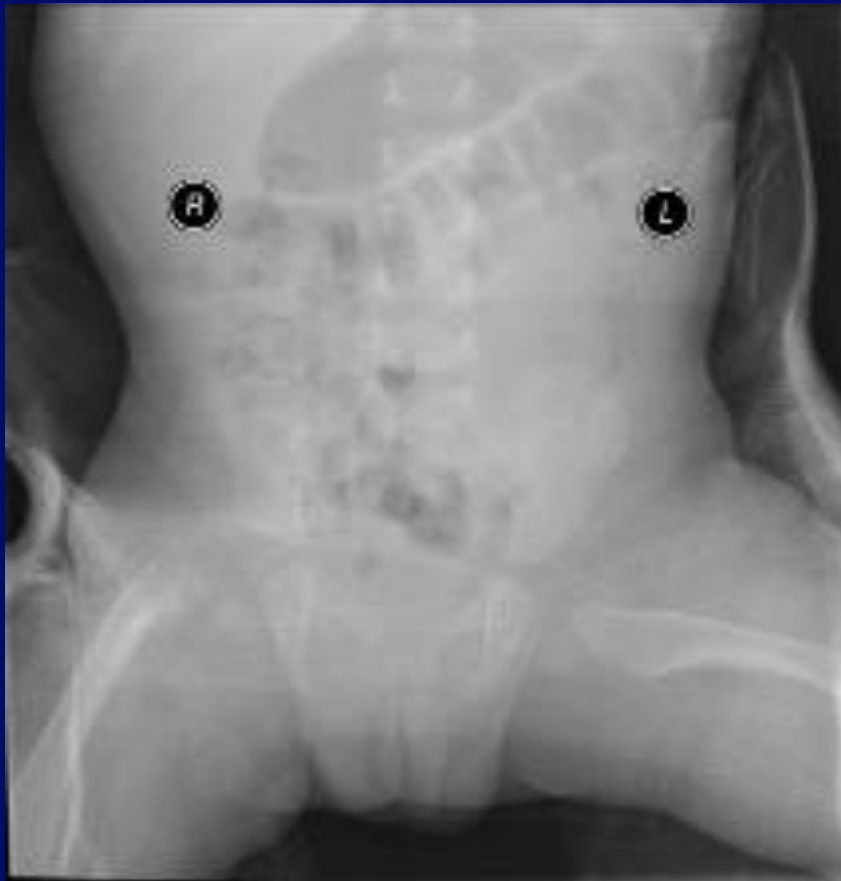
Right hip: Femoral head rotated and displaced anteriorlaterally.

11 month-old male with DDH



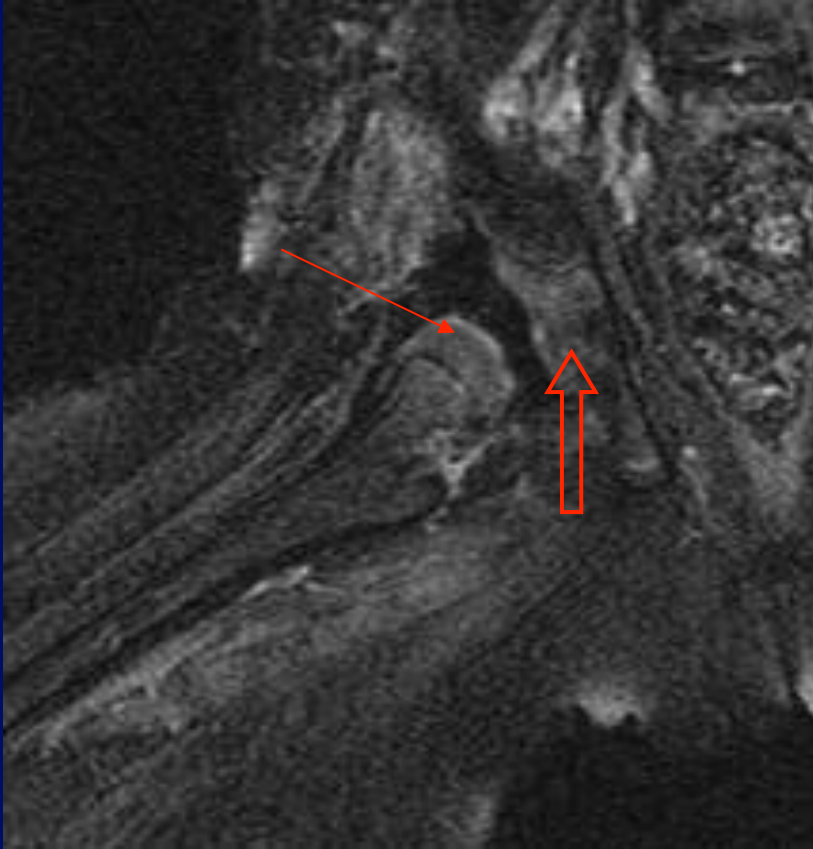

T2 FSE Coronal Left hip: Femoral head abutting acetabulum (**thin arrow**), with deformed acetabular fossa (**open arrow**).

Follow-up of 10 month old male with left hip dislocation, s/p closed reduction with spica cast

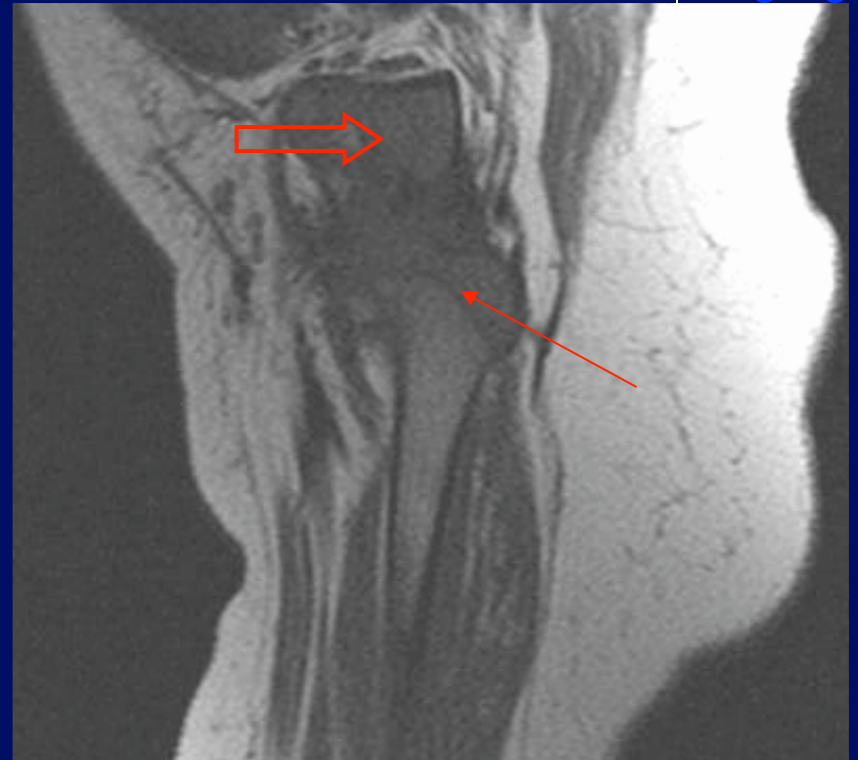


Coronal T2 Fat Sat Left Hip: Femoral head (thin arrow) located anteriomedially in shallow acetabulum (open arrow).

11 month old with DDH




Coronal T2 Fat Sat Right Hip




Sagittal T1 Right Hip

Small dysplastic femoral head is posteriorly subluxed (arrow).
The acetabulum is shallow and dysplastic (open arrow).

Hip Dysplasia/ Dislocation in Congenital Disorders

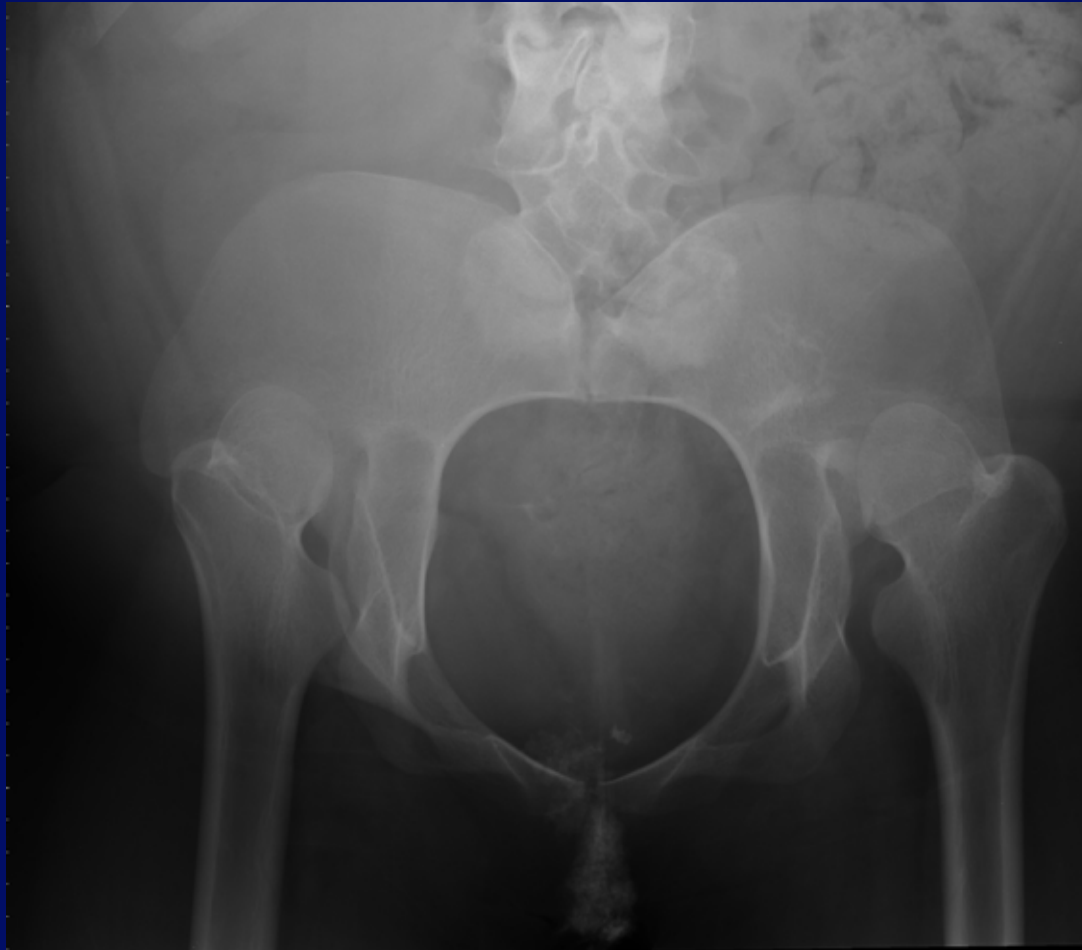



Hip Dysplasia/Dislocation in Congenital Disorders



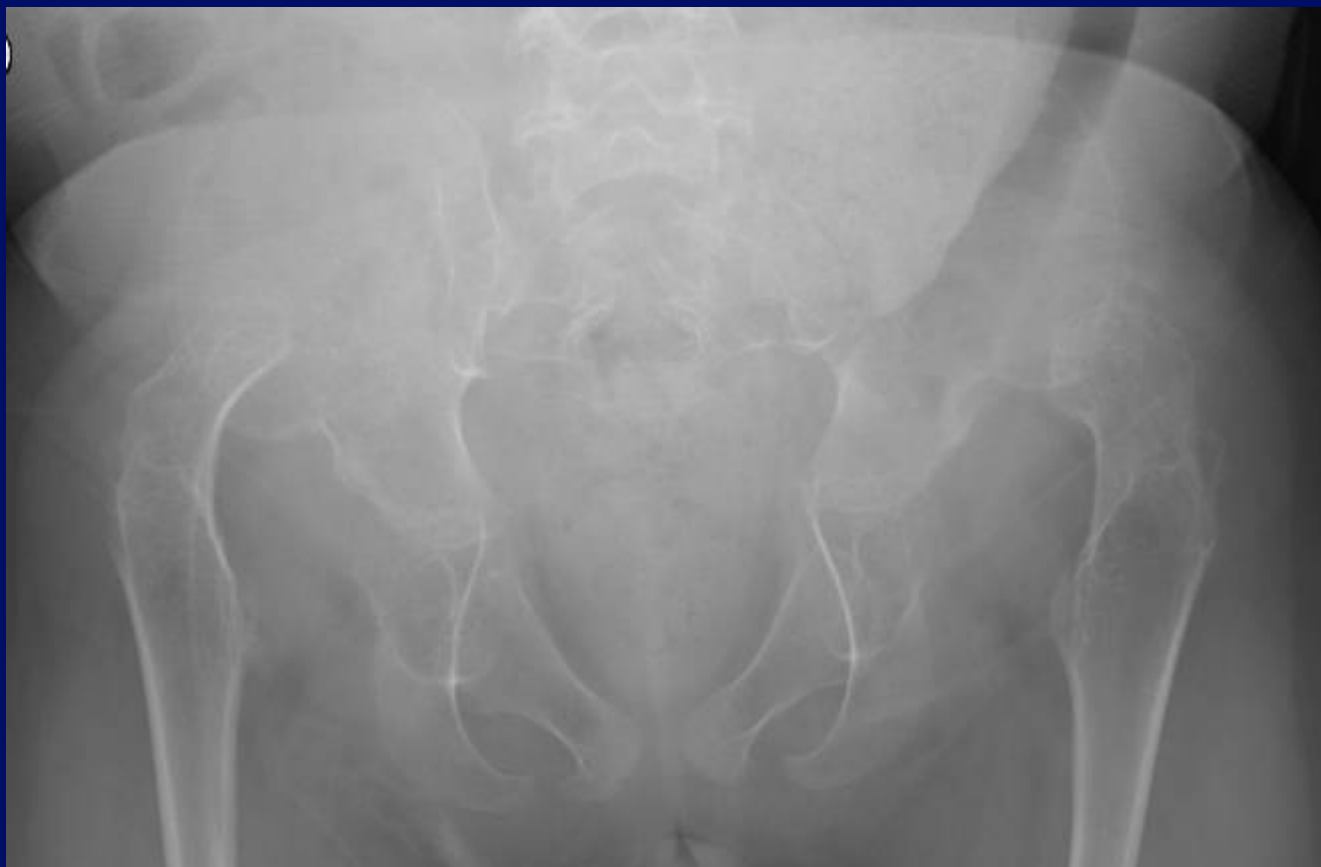
- Several congenital disorders may prompt further evaluation of the hips beyond the routine clinical exam for early diagnosis and management of hip dysplasia.
- Hip dysplasia/dislocation present in congenital disorders tend to be teratologic (not in the spectrum of DDH).

Caudal Regression/Sacral Agenesis



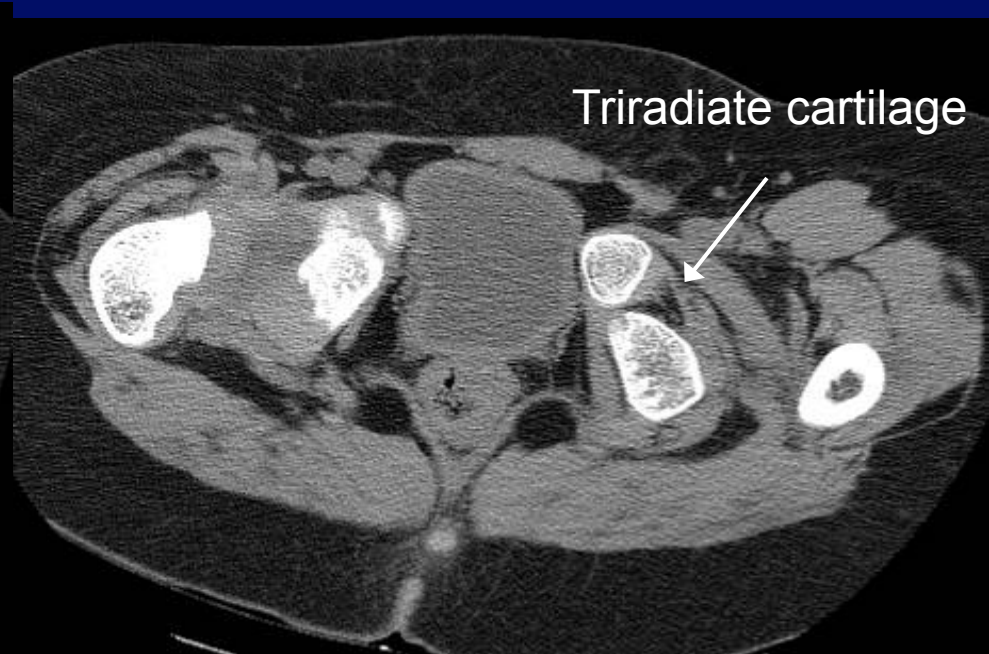
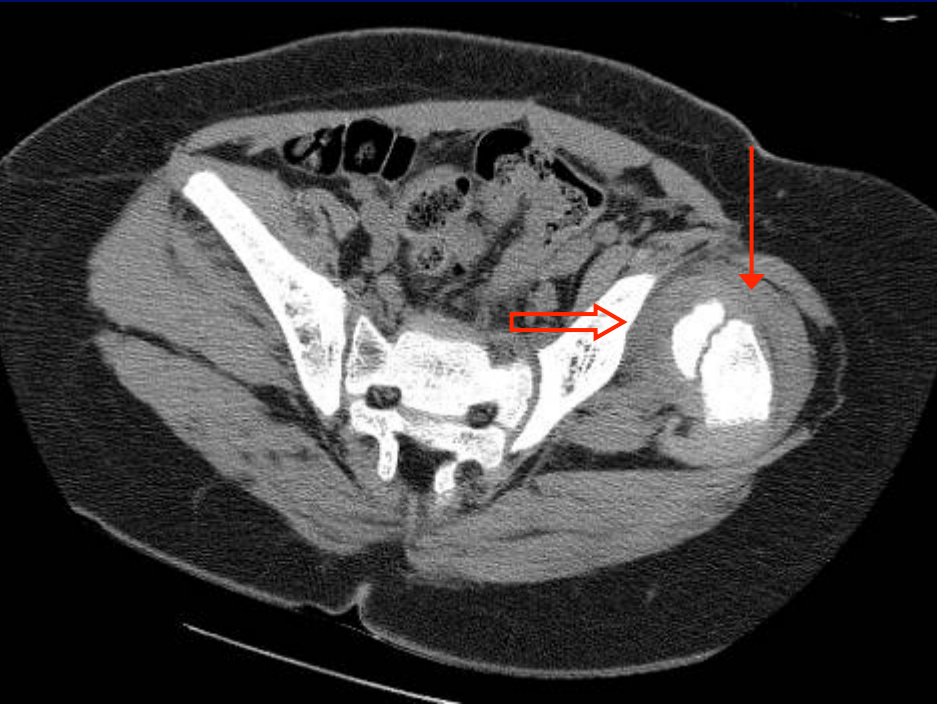
19 year-old female with pelvis deformity including bilateral hip dislocation with pseudoacetabulum formation at the iliac bones and absent coccyx, sacrum, and lower two lumbar vertebrae.

Morquio's Syndrome (mucopolysaccharidoses)



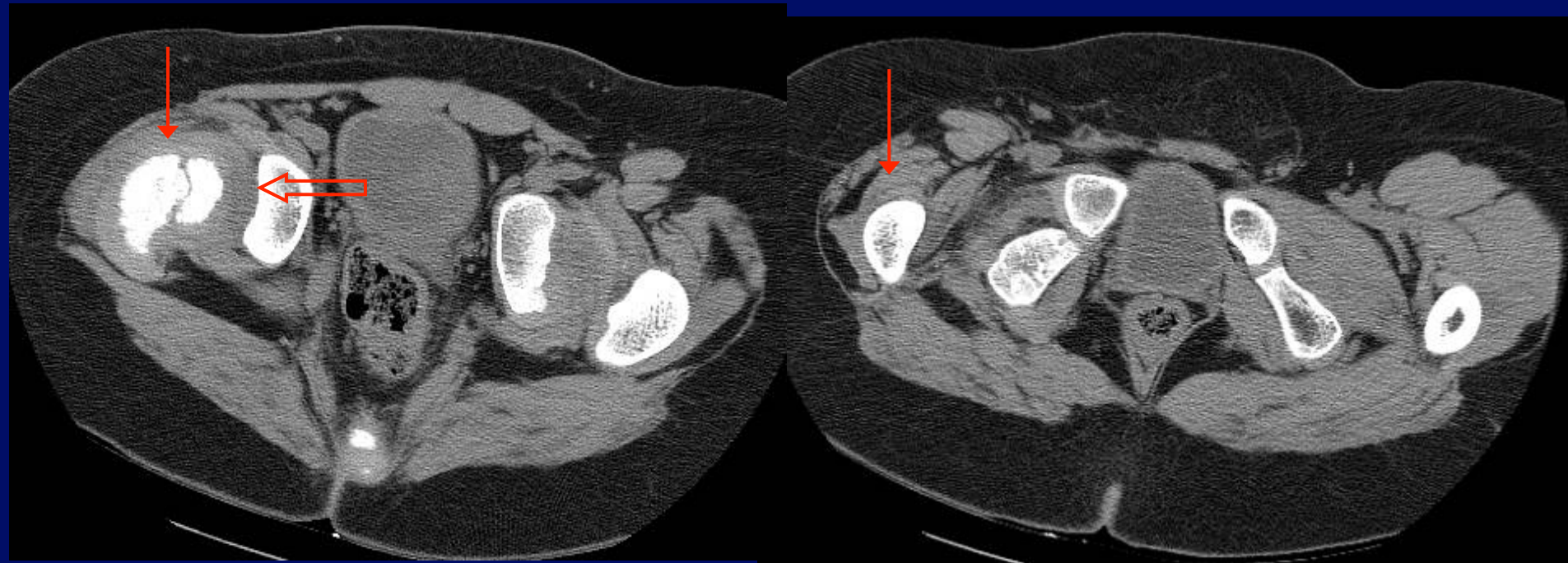
8 year-old female with bilateral high dislocated hips
with acetabular dysplasia.

5 yo male with bilateral DDH and Hx of absent ACL/PCL (Larsen's syndrome?)



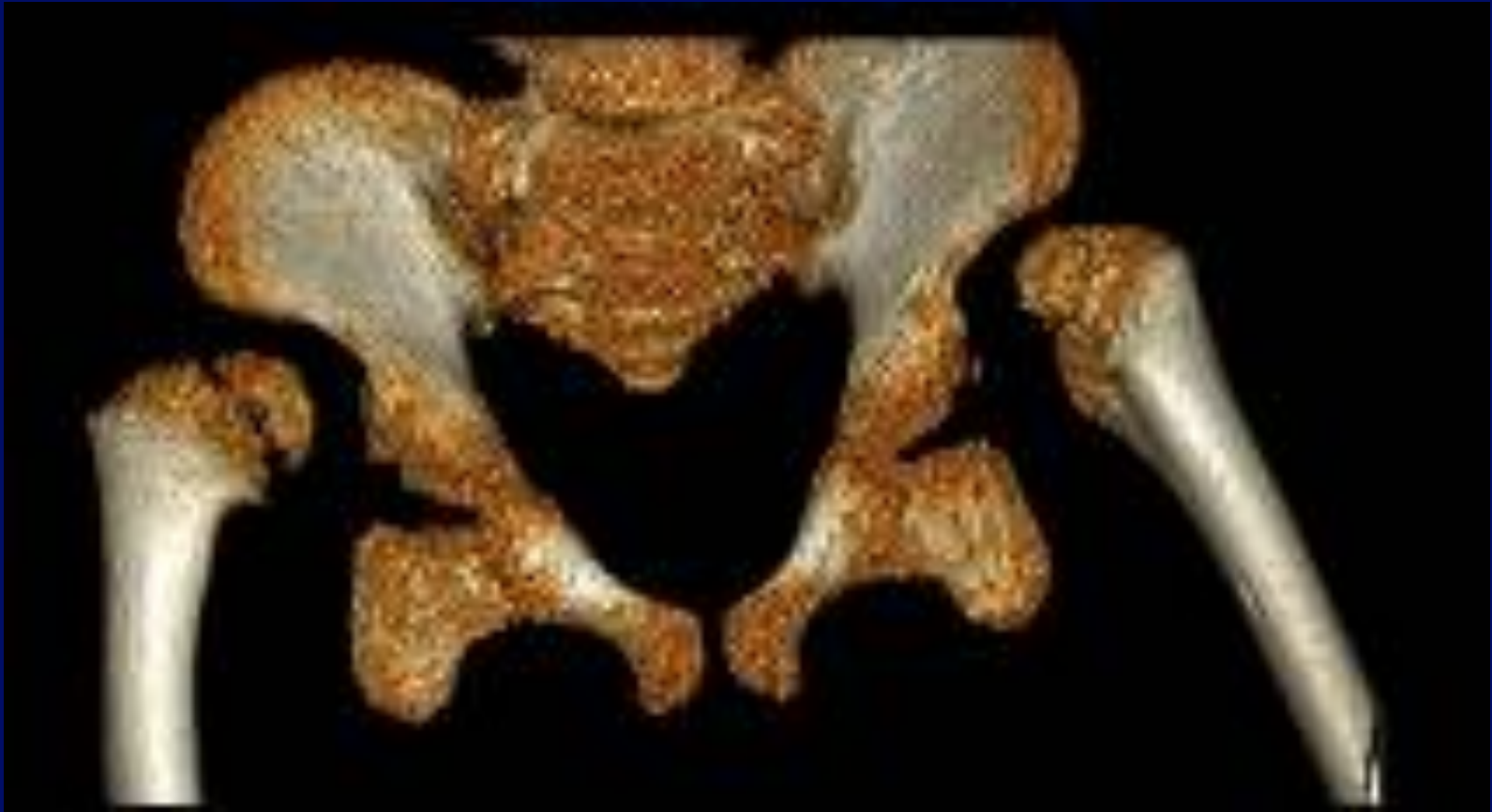

Left Hip: Superior and posterior dislocation of femur (**thin arrow**), head not situated in acetabulum, formation of pseudoacetabulum (**open arrow**).

5 yo male with bilateral DDH and Hx of absent ACL/PCL (Larsen's syndrome?)




Right hip: Lateral and superior dislocation (thin arrows) with formation of pseudoacetabulum (open arrow).

5 yo male with bilateral DDH and Hx of absent ACL/PCL (Larsen's syndrome?)




Pseudoacetabulum formation

Other Congenital Abnormalities with Hip Dysplasia/Dislocation




- Cerebral Palsy
- Arthrogryposis multiplex
- Congenital Myopathy
- Ehlers-Danlos




Differential Diagnosis of DDH

- Various teratologic hip disorders
- Proximal femoral focal deficiency (PFFD)
- Septic hip

Current Management




Infants with **SUBLUXABLE** Hips




- Subluxable hip – hip can move but cannot be completely dislocated (no clunk on exam)
- May just follow with weekly ultrasound for 3 wks, if dysplasia persists – initiate Pavlik harness

Infants with DISLOCATED or SUBLUXED Hips



STEPS:

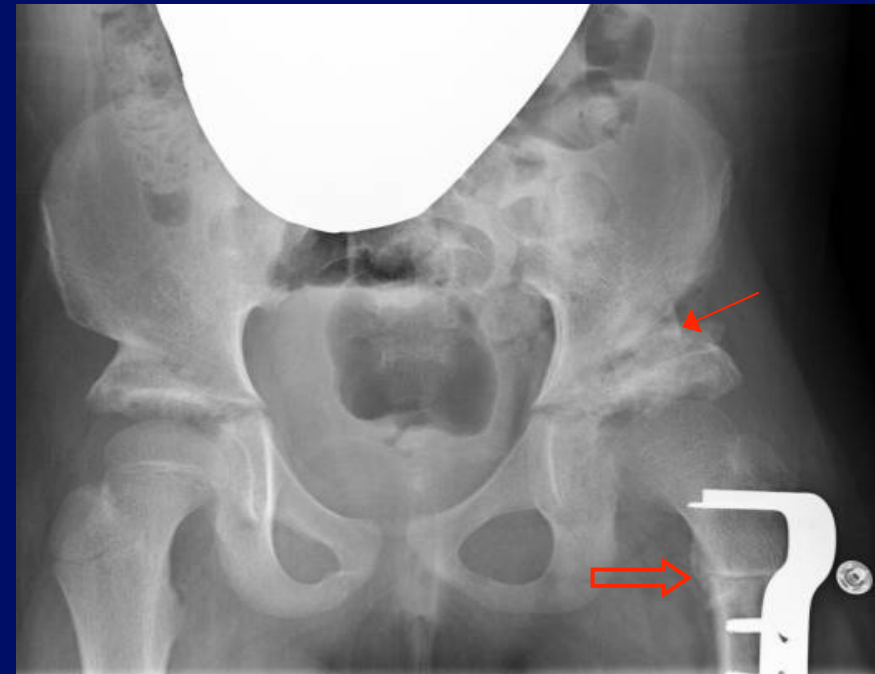
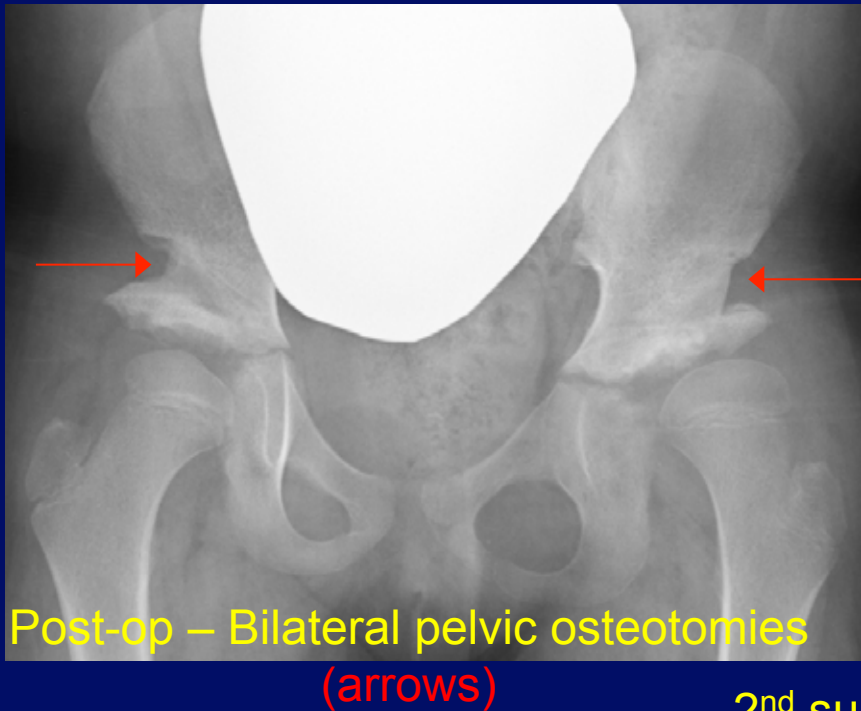
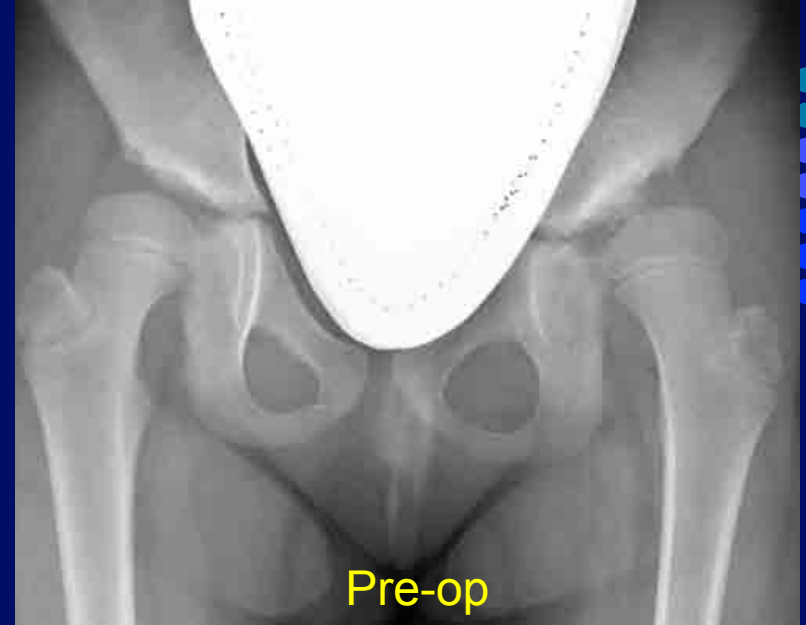- 1) Apply Pavlik harness after clinical diagnosis, then obtain U/S.
- 2) Then do clinical and U/S follow-up weekly.
- 3) At 3 wks, if the hip is:
 - **Reduced** – Continue with harness until normal exam, U/S, and x-ray. Follow-up at 4-6 wks.
 - **Questionable (unstable but reducible)**: Do fixed abduction brace for 3 wks. Afterwards, if the hip is stable, then do Pavlik harness. If it is unstable, follow “Not-Reduced” protocol below.
 - **Not Reduced** – Closed reduction + arthrogram, possible open reduction with cast.



Treatment in Older Children

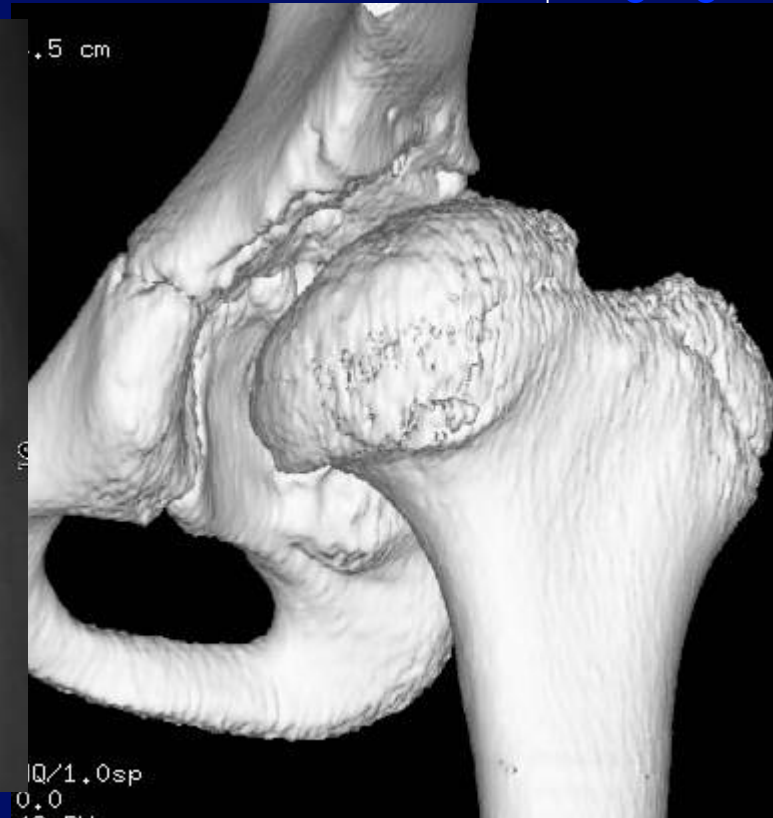
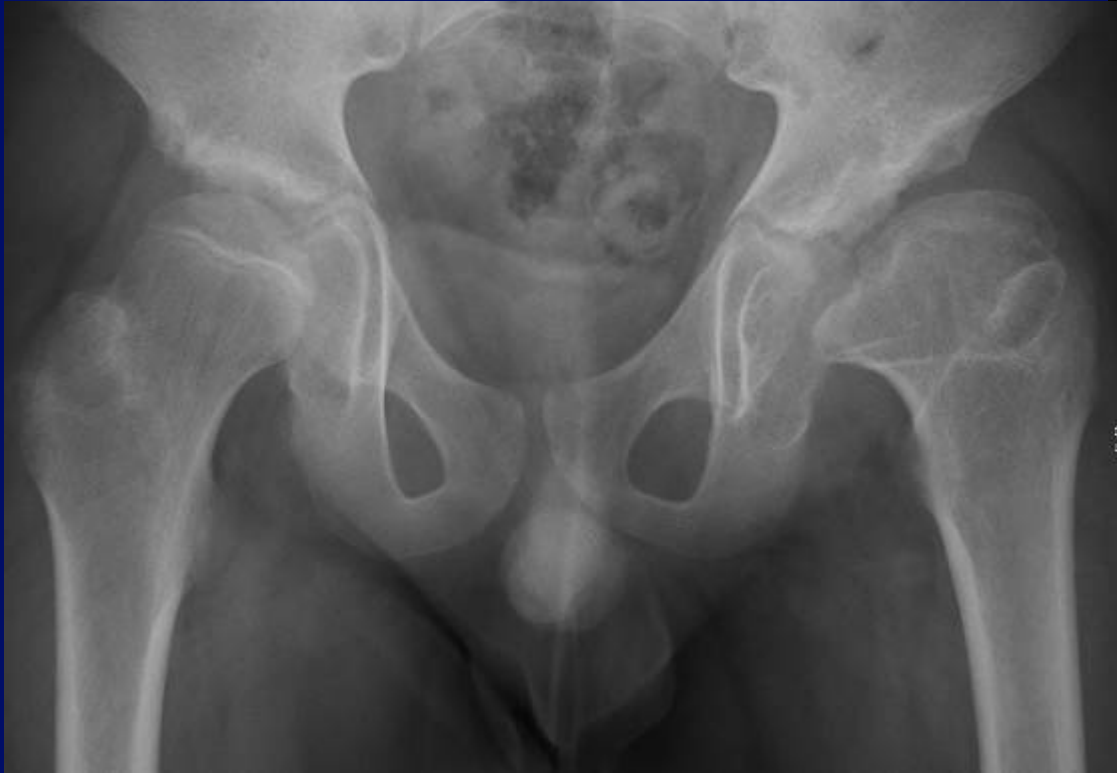- 6 – 18 months of age: Surgical reduction if Pavlik and/or closed reduction have failed.
- 18 months and older: Open reduction, femoral or iliac osteotomies.
- Osteotomies re-position the acetabular roof for improved coverage of the femoral head to encourage proper development of the hip joint.

Example of Osteotomies: DDH in 7 year-old female




2nd surgery, post-op: Revised left pelvic osteotomy,
(thin arrow), new femoral osteotomy (open arrow)

Treatment Complications - AVN




8 year-old male with history of previously treated DDH. The femoral head is wide and flattened with a short neck, consistent with avascular necrosis.

Conclusion




- DDH is a wide spectrum of conditions that range from primary dysplasia without instability to severe, unreducible dislocation with a multifactorial etiology.
- Evaluation: Clinical diagnosis, ultrasound, and radiographic evaluation are primary – imaging features helpful to the orthopedic surgeon are: alpha angle and femoral head position on US; acetabular/CE angles, head position, and Shenton's arc on radiographs.
- CT is helpful for pre-op evaluation in older children or to document reduction; MRI helpful for difficult cases and treatment complications.
- Hip dysplasia/dislocation may be associated with various congenital disorders – usually contain teratologic hips.
- Treatment (hip relocation) includes Pavlik harness, fixed abduction brace, closed reduction, and open reduction with cast (osteotomies).

References



- DD Aronsson, MJ Goldberg, TF Kling, Jr, and DR Roy. Developmental dysplasia of the hip. *Pediatrics* 1994, 94: 201-208.
- Vitale MG, Skaggs DL. Developmental dysplasia of the hip from six months to four years of age. *J Am Acad Orthop Surg* 2001, 9: 401-11.
- Nelitz M, Guenther KP, Gunkel S, Puhl W. Reliability of radiological measurements in the assessment of hip dysplasia in adults. *Br J Radiol* 1999, 72:331-4.
- Gerscovich EO. A radiologist's guide to the imaging in the diagnosis and treatment of developmental dysplasia of the hip. *Skeletal Radiol* 1997, 26: 386-97.
- Graf R. Guide to sonography of the infant hip. New York: Thieme, 1987.
- Wientroub S, Grill F. Ultrasonography in developmental dysplasia of the hip. *J Bone Joint Surg Am* 2000, 82:1004-1018.
- American Academy of Pediatrics: Clinical Practice Guideline: Early Detection of Developmental Dysplasia of the Hip. *Pediatrics* 2000, 105: 896-905.
- Murray KA, Crim JR. Radiographic imaging for treatment and follow-up of developmental dysplasia of the hip. *Seminars in ultrasound, CT, and MR* 2001, 22: 306-44.

References



- Omeroglu H, et al. Measurement of center-edge angle in developmental dysplasia of the hip: a comparison of two methods in patients under 20 years of age. *Skeletal Radiol* 2002, 31: 25-29.
- Broughton NS, et al. Reliability of radiological measurements in the assessment of the child's hip. *JBJS (Br)* 1989, 71-B:6-8.
- Tonnis D. Normal values for the hip joint for the evaluation of x-rays in children and adults. *Clin Orthop* 1976, 119: 39-47.
- Ogata S, et al. Acetabular cover in congenital dislocation of the hip. *JBJS Br* 1990, 72:190-96.
- American Academy of Pediatrics: Clinical Practice Guideline: Early Detection of Developmental Dysplasia of the Hip. *Pediatrics* 2000, 105: 896-905 .
- Fayad LF, Johnson P, Fishman EK. Multidetector CT of Musculoskeletal Disease in the Pediatric Patient: Principles, Techniques, and Clinical Applications. *Radiographics* 2005, 25:603-618.
- Ogata S, Moriya H, Tsuchiya K, et al. Acetabular cover in congenital dislocation of the hip. *J Bone Joint Surg [Br]* 1990, 72:190–6.
- Harcke HT, Grissom LE. Pediatric hip sonography. Diagnosis and differential diagnosis. *Radiol Clin North Am.* 1999, 37:787-96.