



PITUITARY TUMORS: A PRIMER

UR Medicine Pituitary Program

Edward Vates, MD, PhD, FACS
Professor
Neurosurgery, Endocrinology & Otolaryngology
Co-Director

Ismat Shafiq, MBBS
Associate Professor
Endocrinology
Co-Director

Catherine Hastings, A-NP
Nurse Practitioner
Neurosurgery

Specialized Care: Patients with pituitary tumors need coordinated multidisciplinary care from a neurosurgeon & an endocrinologist who work together. This is the focus of the UR Medicine Pituitary Program.

Hormone Labs: A complete endocrine panel helps with initial diagnosis & management: LH, FSH, TSH, free T4, prolactin, ACTH, GH, IGF-1, estradiol (women & men), testosterone free and total (men), and cortisol.

MRI: If you are going to get an MRI, it should be a 1.5 Tesla closed MRI, and specifically a pituitary MRI with dynamic contrast. 3 Tesla MRI is better; it provides better resolution for small pituitary tumors. If your patient cannot have contrast get a pituitary MRI without contrast. If your patient cannot have an MRI, then consider a CT angiogram or CT sinuses.

Classification

There are many different tumors that can arise in the pituitary/sellar region (see right). We will focus on PITUITARY ADENOMAS because they are the most common.

1 in 5 persons has a pituitary tumor...more common than you think!

While common, tumors are often asymptomatic (see below: *The pituitary incidentaloma*)

Pituitary adenomas fall in two broad categories: endocrine-active & endocrine-inactive (aka “null cell” or non-functioning). Endocrine-active tumors are much more common (2:1) and are further classified based on the hormone secreted by the tumor:

Cell Type	Disease
ACTH	Cushing’s disease
GH	Acromegaly
Prolactin	hyperprolactinemia
TSH	(extremely rare)

Pituitary/Sellar Tumors:
 90% → Pituitary adenoma
 Rathke cleft cyst
 Pars intermedia cyst
 Craniopharyngioma
 Epidermoid tumor
 Colloid cyst
 Chordoma
 Meningioma
 Metastatic carcinoma
 Inflammatory/infiltrative disorders

Common presenting symptoms and work-up

Endocrine-inactive adenomas present with symptoms related to mass effect: hypopituitarism, cranial nerve compression, & headache.

Headache is very common in patients with pituitary tumors, but lots of patients have headaches and no tumor, and lots of pituitary tumor patients don’t have headaches...in other words, surgery might make the patient’s headache better but there is no guarantee, and headaches is NOT a compelling reason to treat a tumor (especially a microadenoma).

Hypopituitarism only sets in when the tumor is a macroadenoma (macroadenoma > 1cm, microadenoma < 1cm). Increasing pressure on the normal pituitary gland causes hormone dysfunction in the following order: depressed GH/IGF-1 → depressed LH/FSH (hypogonadotropic hypogonadism) → elevated prolactin (hyperprolactinemia) → depressed TSH (central hypothyroidism) → depressed ACTH (hypocortisolemia leading to Addison’s disease).

Cranial nerve compression typically presents with compression of the optic chiasm that sits over the sella, causing bitemporal hemianopsia, but if there is compression or invasion of the cavernous sinuses you can also have diplopia (CN III, IV or VI) or facial numbness (trigeminal nerve), although this is rare.

Hand icon: Symptoms & signs of hyperprolactinemia depend on sex, and in women the effects depend on hormonal status (see below), but in all pre-menopausal women it is *critical* to exclude pregnancy.

Hand icon: Hyperprolactinemia due to compression (aka *stalk effect*) almost never exceeds 200...anything over that is an endocrine-active prolactinoma. Conversely, anything < 150 may respond to bromocriptine/cabergoline, but drug Rx may not actually be treating the tumor, merely suppressing the effect of stalk compression.

Endocrine-active adenomas present with symptoms related to the hypersecretion syndrome, and rarely from mass effect (prolactinomas in men are the exception to this rule)

ACTH-Cushing's disease

Central adiposity, diabetes, hypertension, hirsutism, acne, depression/anxiety, connective tissue fragility, striae, easy bruising, osteopenia/porosis, hypercalcuria, steroid myopathy

GH-Acromegaly/Gigantism

Soft tissue swelling, prognathism, frontal bossing, deep voice, sleep apnea, joint pain, excessive sweating, diabetes or impaired glucose tolerance, carpal tunnel, cardiomegaly, hypertension

Prolactinoma

Pre-menopausal women: amenorrhea, galactorrhea, decreased libido
Post-menopausal women: breast tenderness, decreased libido, decreased bone mineral density
Men: decreased libido, impotence

👉 1/3 of GH-secreting adenomas co-secrete prolactin, so JUST CHECKING A PROLACTIN LEVEL ISN'T ENOUGH

Diagnosis depends on the hypersecreted hormone:

- 1) confirm hypercortisolemia: check midnight salivary cortisol OR 24-hour urine free cortisol AND SERUM ACTH
- 2) confirm ACTH-dependent hypercortisolemia: measure a.m. ACTH & cortisol simultaneously
- 3) confirm pituitary source: check low/high dose dexamethasone suppression test & IPSS (see below)
- 4) check MRI

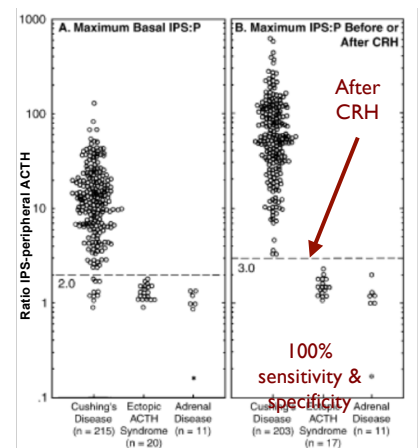
- 1) check IGF-1 (GH is pulsatile but IGF-1 summates the effects)
- 2) confirm GH abnormality: check oral glucose tolerance test
- 3) check MRI

- 1) confirm hyperprolactinemia: check serum prl (>200 ng/dl) make sure to do dilutions make sure to check for GH & IGF-1
- 2) make sure patient isn't pregnant: check β -HCG if premenopausal
- 3) rule out hypothyroidism: check TSH & free T4
- 4) if prl between 50-200, make sure there are no other medical factors
- 5) check MRI

↓
1.5 – 3 Tesla closed MRI pituitary protocol with dynamic contrast study

👉 Hyperprolactinemia can be due to MANY causes. In pre-menopausal women ALWAYS RULE OUT PREGNANCY. Other causes: hypothyroidism, medications including many psychiatric medications (phenothiazines, MAOI's, fluoxetine, butyrophenones, tricyclics, and amoxipine), antihypertensives (methyldopa, Ca⁺²-channel blockers and reserpine), estrogens, metoclopramide, H₂-receptor blockers (cimetidine, ranitidine), and opiates, renal failure, liver failure, breast stimulation, other conditions that can mimic breast stimulation (e.g., chest wall or spinal cord lesions), stress and seizures.

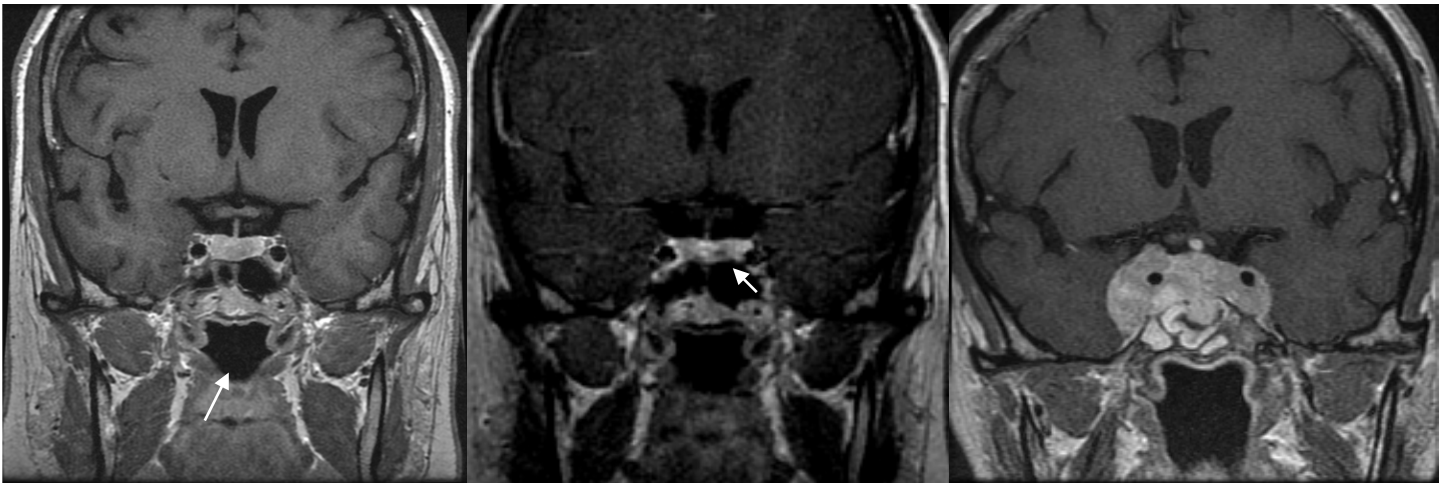
What is inferior petrosal sinus sampling (IPSS)? This helps determine if hypercortisolemia is due to a pituitary tumor. Doctors in the Pituitary Program can sample the blood from the pituitary gland, and compare the ACTH level to the peripheral ACTH level before and after injection of corticotrophin releasing hormone (CRH, the hypothalamic stimulant for ACTH release from the pituitary). Before CRH injection, 95% of patients with a pituitary adenoma causing Cushing's will have an IPSS/peripheral ACTH ratio ≥ 2 (because the tumor secretes ACTH that feeds into the IPSS). However, the sensitivity and specificity of the test increases to 100%/100% by injecting CRH and measuring the IPSS/peripheral ratio again; an ACTH-secreting pituitary adenoma will still respond to CRH, and an IPSS/peripheral ratio ≥ 3 is incontrovertible evidence of Cushing's disease. (figure from Oldfield EH, Doppman JL, Nieman LK, et al. N Engl J Med 1991;325(13):897-905). Note however that IPSS cannot always be performed successfully because of variations in individual anatomy of the venous sinuses and should only be done at a center (like UR Medicine) where doctors perform this frequently.



Imaging

MRI is mandatory for the evaluation of pituitary tumors, and in most cases no treatment recommendations can be made without a high quality study that allows for accurate and precise description of the anatomy. Most MRI facilities in Upstate NY are able to perform MRI with a pituitary imaging protocol developed by the UR Medicine Pituitary Program in conjunction with our radiology colleagues, using post-contrast coronal and sagittal images, and dynamic contrast imaging.

What is a dynamic contrast MRI? Almost all pituitary tumors enhance, but so does the normal pituitary gland...in fact it enhances even more. However, compared to the normal pituitary gland (which enhances quickly), most pituitary adenomas enhance more slowly because of the disorganized microvasculature. You can take advantage of this using a dynamic contrast study; even small pituitary tumors (as small as 1-2 mm) will show up when the MRI images are acquired while the contrast is being injected because the normal pituitary gland will start to enhance before the tumor, thereby showing the tumor more accurately as a dark "shadow" within the brightly-enhancing, normal pituitary gland.



A small Cushing's tumor is invisible on the regular post-contrast MRI scan.

The small tumor is only visible on the dynamic contrast study.

Not all tumors require a dynamic contrast study to be seen; this patient's prolactin level was >9000.

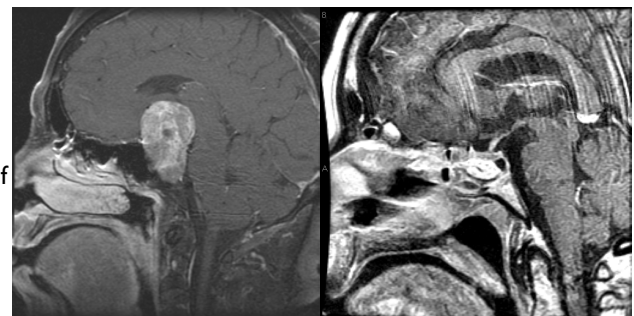
Management decisions: medical, surgical and radiation options

Goals of therapy depend on many factors: endocrinopathy (hypersecretion/hypopituitarism), symptoms from compression, tumor size and relationship to normal anatomy, patient age and medical comorbidities. For most patients, the UR Medicine Pituitary Program offers a combination of medical, surgical, and other therapies that can control their symptoms, prevent tumor progression, and in many cases patients can even be cured. This requires close collaboration between caregivers from many different disciplines. In addition, even a "cured" patient must always follow-up because remote recurrences can occur.

When is surgery appropriate? Any patient with Cushing's disease or acromegaly has a potentially life-threatening hormone problem. Surgery offers a chance for cure when the tumor is small and the surgeon is experienced. Cushing's tumors can be especially small (many are symptomatic at 1-2 mm size) so finding the tumor is critical and the surgeon's experience is the most important factor. Even when a cure is achieved, there is a 25-30% recurrence rate because Cushing's tumors can be highly invasive microscopically. Acromegalic tumors often present insidiously, and as a result many are too large to achieve a cure with surgery, but debulking of the tumor reduces the level of endocrinopathy and allows for tailored medical or radiation treatment.

Endocrine-inactive tumors > 1 cm in size (macroadenomas) should be considered for surgery. Macroadenomas cause pituitary compression and eventually hypopituitarism, but if the patient is asymptomatic then they can be watched. The patient needs to be counseled on the risks of pituitary apoplexy (see below) and the unknown effects of asymptomatic hypopituitarism. Obviously very large tumors should be seriously considered for resection even if asymptomatic.

Endocrine-inactive tumors < 1 cm (microadenomas) are unlikely to be causing hypopituitarism due to compression, and certainly are not big enough to cause other problems due to mass effect; these tumors may remain stable in size and can be followed radiographically and considered for resection if they show growth.



A pituitary macroadenoma in a post-menopausal woman with headaches, decreased libido and bitemporal hemianopsia.

Post-op MRI shows complete resection of the tumor with preservation of the normal pituitary sitting over residual fat graft.



Endoscopic surgery: Patients don't see the incision, surgery takes 2 hours, and most patients go home the next day. We've done over 600 surgeries at URM, and we are the busiest program in NY State with the shortest length of stay and the lowest cost.

Medical therapies for pituitary adenomas:

PROLACTINOMAS: Even very large prolactinomas should be treated first with medication. Dopamine agonists can normalize prolactin levels in the vast majority of patients and 69% of patients show a >25% reduction in tumor size (40% have >50% reduction in size). Bromocriptine and cabergoline are now both available in generic forms, and cabergoline is preferred because of fewer side effects (nausea, vomiting and orthostatic hypotension being the most frequent with either Rx), duration of action (twice weekly vs. daily dosing), and it is more effective at reducing the size of tumors. Bromocriptine is used in women who want to become pregnant, because the safety profile for cabergoline in pregnancy is not established. In rare cases, surgery may be recommended in patients who cannot tolerate medical Rx or if the patient is young and doesn't want to take medication lifelong.

ACROMEGALY: Octreotide (Sandostatin) is a somatostatin analogue administered subcutaneously and it reduces GH/IGF-I in 80-90% of patients, although it normalizes these values in only 40-50% of patients. It has a short half-life, requiring multiple injections daily; a long-acting form is now available, requires dosing q4-6 weeks, and appears to be more effective, but can be associated with diarrhea and abdominal pain. Pegvisomant (a GH receptor inhibitor) is also available in the US as a second line treatment, but does not reduce tumor burden.

CUSHING'S DISEASE: Drug Rx for Cushing's disease is suboptimal; surgery is the first treatment recommendation and, if this is unsuccessful, return to a eucortisolemic state through bilateral adrenalectomy with hydrocortisone replacement. In recent years new medical approaches have become available for the treatment of Cushing's. These approaches include pasireotide (a somatostatin analogue), cabergoline, and the glucocorticoid-receptor antagonist mifepristone. These agents are recommended in situations in which surgery does not control the disease. In addition, older therapies aimed at interfering with cortisol synthesis remain available. The UR Medicine Pituitary Program is one of a few centers in the country providing clinical trials for medical treatment of Cushing's.

Radiation therapies for pituitary adenomas: Radiotherapy remains an important adjunct for treating patients with endocrine-active and endocrine-inactive pituitary adenomas that persist after surgery, are inoperable, or are resistant to medical therapy. Radiotherapy can be either stereotactic radiosurgery (SRS) or fractionated radiation therapy (FRT). Control of tumor growth is >95% with either therapy, but studies suggest that endocrine-active adenomas respond more quickly to SRS than to FRT. The durability of remission remains uncertain because most SRS studies do not have >5-10 year follow-up. Interestingly, ACTH-secreting tumors appear to be the most radiosensitive, with one study showing a 100% response rate. It is uncertain whether hormone-suppressing medication during radiotherapy decreases the response to radiation, and for SRS the safety profile remains unproven. Risk to the optic nerves appears to be low, with most studies showing very few patients with complaints of new vision problems, although the sensitivity of patient complaints may be lower than formal visual field testing. We are currently using fractionated stereotactic radiotherapy (SRT) for patients who are not candidates for SRS; this merges the use of standard linear accelerators with highly conformal delivery systems to provide therapy to small volumes that minimize the risk of hypopituitarism, and we are currently engaged in a study to compare SRT to SRS and FRT.

Pituitary Apoplexy

This is the most dreaded consequence in patients harboring a pituitary adenoma, but fortunately it is very rare, constituting 1-2% of patient presentations in most large series. The syndrome is defined as: sudden onset headache, nausea, vomiting, visual disturbances, oculomotor paresis, progressing to drowsiness, altered mental status and sometimes coma in a 24-48 hr timeframe. It usually arises because of sudden change in tumor size due to tumor infarction or intra-tumoral hemorrhage. This is a clinical not a radiographic diagnosis (i.e., an MRI showing hemorrhage in a pituitary tumor does not equate with pituitary apoplexy). The treatment is immediate steroid replacement (hydrocortisone 100 mg iv) and transsphenoidal exploration to decompress the pituitary region and to provide diagnosis in patients without a history of pituitary adenoma (other possible causes of pituitary apoplexy include abscess, metastatic tumor, lymphocytic hypophysitis, or hemorrhage associated with pregnancy). With timely intervention, this is rarely a fatal condition and most patients have return of visual function, but hypopituitarism usually persists.

The pituitary "incidentaloma": what do you do when your patient gets a scan for an unrelated reason?

Autopsy series suggest a prevalence of 10-12% for pituitary tumors (micro- and macroadenomas), and immunohistochemical evidence suggests 40-50% are prolactin (+). With increasing use of CT and MRI, more pituitary "incidentalomas" are being discovered, raising concern about what to recommend to patients harboring asymptomatic lesions; patient and physician anxiety must be balanced by what we know about pituitary tumors and the costs of unnecessary tests. Negative tests provide reassurance and improve quality of life, but extensive testing is expensive and may result in further expense and harm as false positive tests are pursued, creating a chain of events that proceeds with increasing momentum until it is difficult to stop. In general, we recommend the following for an incidentally discovered microadenoma: a one-time full endocrine screening panel, and a follow-up MRI in one year. If the endocrine tests are normal and the follow-up MRI shows no tumor growth, then a yearly prolactin level and IGF-I test are sufficiently sensitive to detect the most likely "bad" developments: increasing tumor size to a macroadenoma (which would cause IGF-I to fall and prolactin to rise) or conversion to an endocrine-active tumor (prolactinomas being the most likely). If symptoms indicate transition into an ACTH-secreting or TSH-secreting tumor, then further testing is needed.

This handout is for informational purposes only, and should not be construed as definitive treatment recommendations. Medical knowledge is constantly evolving, and this information cannot substitute for current state-of-the-art medical therapy.

References

- Daly, AF, Burlacu, MC, Livadariu, E, Beckers, A. The epidemiology and management of pituitary incidentalomas. *Horm. Res.* 2007, 68(suppl 5): 195-198.
- Dubuisson, AS, Beckers, A, and Stevenaert, A. Classical pituitary tumour apoplexy: clinical features, management and outcomes in a series of 24 patients. *Clinical Neurol. & Neurosurg.* 2007, 109: 63-70.
- Greeman, Y, and Melmed, S. Diagnosis and management of nonfunctioning pituitary tumors. *Annu. Rev. Med.* 1996, 47: 95-106.
- Findling, JW, Raff, H. Cushing's syndrome: important issues in diagnosis and management. *J Clin. Endocrin. & Metabol.*, 2006, 91(10): 3746-3752.
- Freda, PU, and Wardlaw, SL. Diagnosis and treatment of pituitary tumors. *J Clin. Endocrin. & Metabol.* 1999, 84 (11): 3859-3866.
- Hammer, GD, Tyrrell, JB, Lamborn, KR, Applebury, CB, Hannegan, ET, Bell, S, Lu, A, and Wilson, CB. Transsphenoidal microsurgery for Cushing's disease: initial outcome and long-term results. *J. Clin. Endocrin. & Metabol.* 2004, 89(12): 6348-6357.
- King, JT, Justice, AC, and Aron, DC. Management of incidental pituitary microadenomas: a cost-effectiveness analysis. *J Clin. Endocrin. & Metabol.* 1997, 82(11): 3625-3632.
- Kong, DS, Lee, JJ, Kim, DH, Kim, KW, Nam, DH, Park, K, and Kim, JH. The efficacy of fractionated radiotherapy and stereotactic radiosurgery for pituitary adenomas. *Cancer* 2007, 110(4): 854-860.
- Lindsay, JR, and Nieman, LK. Differential diagnosis and imaging in Cushing's syndrome. *Endocrinol. Metab. Clin. N. Am.* 2005, 34: 403-421.
- Minniti, G. Fractionated stereotactic conformal radiotherapy for secreting and nonsecreting pituitary adenomas. *Clinical Endocrinol.* 2006, 64: 542-548.
- Minniti, G, Esposito, V, Piccirilli, M, Fratticci, A, Santoro, A, Jaffrain-Rea, M-L. Diagnosis and management of pituitary tumours in the elderly. *European J. Endocrin.* 2005, 153: 723-735.
- Mitsumori, M. Initial clinical results of linac-based stereotactic radiosurgery and stereotactic radiotherapy for pituitary adenomas. *Int. J. Radiat. Oncol. Biol. Phys.* 1998, 42: 573-580.
- Pickett, CA. Diagnosis and management of pituitary tumors: recent advances. *Prim. Care Clin. Office Pract.* 2003, 30: 765-789.

QUESTIONS OR REFERRALS: (585) 273-2343 EMAIL: pituitary@urmc.rochester.edu

