

Dermatomyositis as Initial Presentation of dMMR Colorectal Cancer and its Treatment Dilemma

Minh Thu T. Nguyen MD, Julia R. Gomez BA, Christine M. Osborne MD
University of Rochester Medical Center, Rochester, NY

Introduction

- Dermatomyositis is a rare rheumatologic condition (13:100,000 per year).
- Features an erythematous rash affecting the face, upper chest and dorsal hands, accompanied by proximal muscle weakness.
- Positive labs include CK, ANA, anti-RNP, TIF-1 gamma Ab, SSA-52 (Ro)
- Dermatomyositis can be paraneoplastic in 7 to 32% of cases.
- Associated malignancies include cervix, lung, ovary, pancreas, bladder and stomach. Colorectal cancer (CRC) is less commonly reported.

Labs

Basic work-up

Na – 128 (L)
 Serum Cr – 0.27 (L)
 K – 4.8 (nl)
 WBC – 11.9 (H)
 Hgb – 11.7 (nl)
 PLT – 478 (nl)
 CK – 239 (H)
 Alk phos – 210 (H)
 AST/ALT – 12 (nl)
 CRP – 15 (nl) ESR – 26 (nl)
 CEA – 1,445 (H)

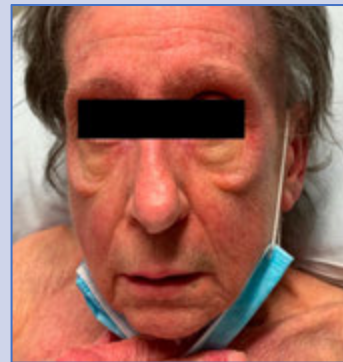Autoimmune work-up

ANA – neg (nl)
 Anti-RNP Ab – 2.5 (H)
 Anti-Smith Ab – <0.2 (nl)
 Anti-DS-dna Ab – 1 (nl)
 Anti-SSA/SSB Ab – 0.3,
 <0.2 (nl)
 Myositis panel:
 TIF-1 gamma Ab – high
 positive
 SSA-52 (Ro) (ENA) IgG Ab
 – 62 (H)

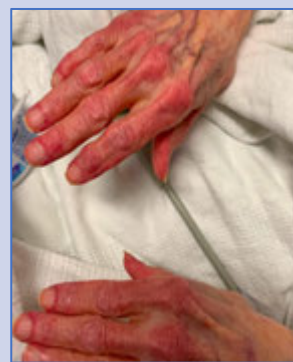
Case Description

A 75-year-old woman developed an erythematous rash of the face and bilateral hands (fig. 1 & 2). The rash was treated with courses of oral steroids by her PCP with remission each time. After 11 months of these symptoms, the patient was hospitalized for a GI bleed. Colonoscopy revealed a 5 cm mass in the ascending colon (fig. 3). Biopsy established dMMR (DNA mismatch repair) CRC and she underwent right hemicolectomy. She was discharged with oncology follow-up for staging.

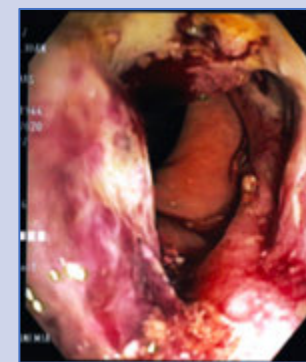
14 months into illness, patient presented to our service for rash recurrence along with progressive proximal muscle weakness that limited ADLs. Labs were notable for elevated CK and positive anti-RNP Ab. Dermatomyositis was confirmed with positive TIF-1 gamma Ab. Extensive metastases in liver, lungs, pelvis, peritoneum, and lymph nodes were seen on CT.



1



2



3

Oncology and Rheumatology jointly decided to treat her dermatomyositis first with intravenous immunoglobulin (IVIG) and pulse-dose steroids, followed by a prolonged oral steroid taper. If her functional status improved, oncology would then proceed with immunotherapy (pembrolizumab). Unfortunately, her metastatic cancer aggressively grew during the prednisone taper. Patient opted for hospice and died 1 week later.

Discussion

- Dermatomyositis may be the initial presentation of an underlying malignancy and delayed surveillance results in further disease progression.
- Importance of age-appropriate malignancy screening in patients with new-onset dermatomyositis
- Screening for CRC or breast cancer would have been appropriate for this patient. (Her last screenings were 12 years prior to presentation.)
- Work-up for dermatomyositis includes CK, ANA, anti-RNP, and myositis panel.
- Treatment of paraneoplastic dermatomyositis is oftentimes treatment of underlying malignancy.
- In this case, there was difficulty targeting her dMMR CRC first because dermatomyositis significantly reduced her functional status, preventing initiation of immunotherapy.
- dMMR CRC responds favorably to immunotherapy over chemotherapy.
- Immunotherapy is often associated with worsening flare-ups of rheumatologic conditions, although paraneoplastic dermatomyositis is not an absolute contraindication to use.